Worsening of Glycemic Control in a Patient With Fulminant Type 1 Diabetes Receiving Sensor-Augmented Pump Therapy: A Case of Extensive Localized Lipoatrophy Requiring Attention in Relation to Cannula Insertion Sites

Keiko Koide,[1] Koichiro Azuma,[2] and Yoshihito Atsumi[1]

Case Presentation

A female patient who had previously been healthy developed fulminant (i.e., extremely acute onset) type 1 diabetes at the age of 50 years. At that time, her C-peptide was below detectable levels, and her plasma glucose was >600 mg/dL, with a near-normal A1C of 6.1%. She tested negative for both anti-GAD and anti-IA-2 antibodies as well as antithyroid autoantibodies (1). She developed localized lipoatrophy (LL) at injection sites after initiating a multiple daily injection (MDI) therapy regimen with insulin aspart and insulin glargine at a previous hospital but had been given no particular instructions on how to deal with LL.

With her glycemic control still found to be inadequate 1 year later, at the age 51 years, despite insulin therapy, she was referred to our hospital so she could be switched to sensor-augmented pump (SAP) therapy. At presentation, she had no diabetic neuropathy, retinopathy, or nephropathy. After switching to SAP therapy with insulin lispro, her A1C improved from 8.3 to 7.2%.

However, at the age of 52 years, after 6 months of SAP therapy, her A1C deteriorated from 7.4 to 8.2%. A review of the SAP troubleshooting history revealed that she had had frequent insulin infusion interruptions. Also, an examination of the cannula insertion sites showed that they were all located from the right abdomen to the lower right abdomen to the midline, with depressions at the insertion sites and their surrounding tissue. There were also sites in the lower navel area from earlier basal-bolus therapy. Thus, LL had grown to affect a wide area that included the lower navel (Figure 1). She had made a practice of inserting cannulas in the right abdomen and placing her glucose sensor on the left, thus continuing to insert cannulas into the same areas that looked depressed as a result of a decrease in subcutaneous fat mass and were characterized by marked atrophy (Figure 2).

Biopsies were performed to examine tissues from a depressed area and a borderline area between the depressed and normal areas. Microscopically, the depressed adipose area showed a reduction in size but no reduction in number; it also showed evidence of inflammatory cell infiltration (i.e., $CD4^+$ T cells and M2 macrophages). The borderline tissue showed a mixture of diminished and normal-sized adipose cells. Electron microscopy revealed the depressed area to be atrophic (about 30 μm in diameter) but to contain no apoptotic cells. No abnormal findings were noted in serum leptin, adiponectin, or immunoglobulin levels or on thyroid function.

Based on these findings, this case was thought to constitute one of acute and extensive LL associated with insulin therapy in a patient with type 1 diabetes whose glycemic control worsened mainly as a result of repeated cannula insertions into lipoatrophic sites, resulting in insulin infusion interruptions. After the diagnosis was established, the insulin formulations were replaced with insulin glulisine, to which she had never been exposed previously. Additionally, she was instructed not only to insert cannulas at sites that were not affected by lipoatrophy, ranging broadly from the

[1]Diabetes Clinical Research Center, Eiju General Hospital, Taito-ku, Tokyo, Japan; [2]Diabetes Center, Nerima General Hospital, Nerima-ku, Tokyo, Japan

Corresponding author: Keiko Koide, koiden@eijuho.com

https://doi.org/10.2337/cd21-0035

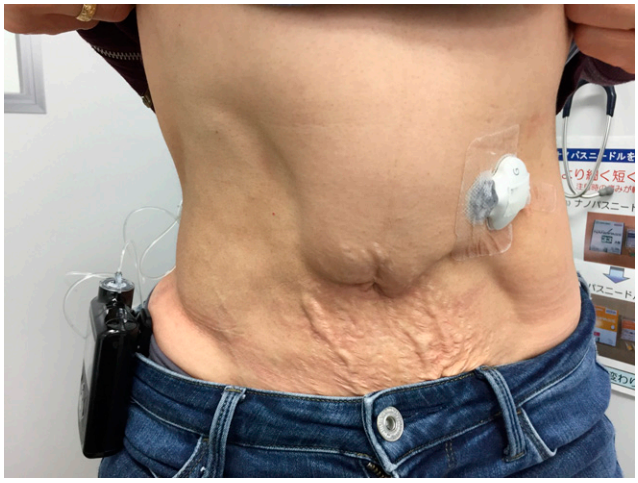

FIGURE 1 Extensive lipoatrophy localized mainly in the right abdomen.

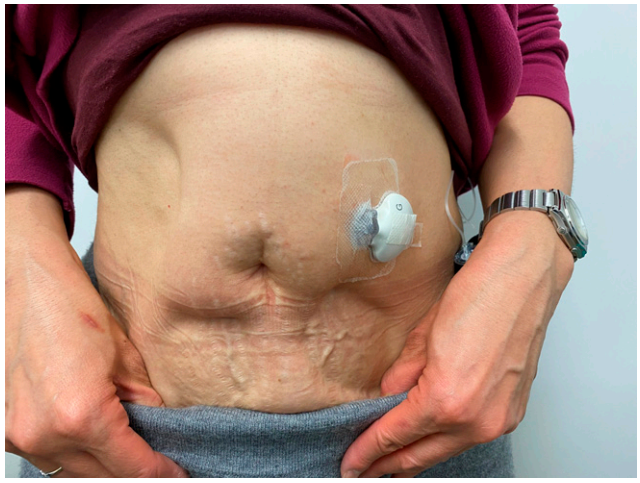

FIGURE 3 A trend toward improvement in LL seen with the use of cannula insertion sites in rotation.

left abdomen to the waist to the hip or thigh, but also to use these insertion sites in rotation.

After instituting these changes, the patient had no further insulin infusion interruptions, and her A1C improved to the 6.8–7.3% range. The extent of lipoatrophy was found to be mild at the new insertion sites, and lipoatrophy gradually improved in the depressed sites, including those in the lower navel (Figure 3).

Question

What should be suspected when a patient with diabetes and LL experiences worsening glycemic control despite switching from an MDI insulin regimen to SAP therapy?

Commentary

Although LL associated with insulin formulations occurs as a result of adipocyte atrophy, its mechanisms of onset are unclear (2,3). Putative mechanisms include influences of an immune response to insulin injections or to excipients of the injection solution, trauma from repeated local injections, inhibitory effects of macrophage-derived cytokines on adipocyte differentiation, and $CD4^+$ T cell–mediated tissue remodeling (4–6). Microscopic photographs of the skin depressions in this case showed evidence of infiltration of inflammatory cells (i.e., $CD4^+$ T cells and M2 macrophages) in parts of the vascular stroma, suggesting the likely involvement of $CD4^+$ T cell–mediated tissue remodeling in the onset of LL.

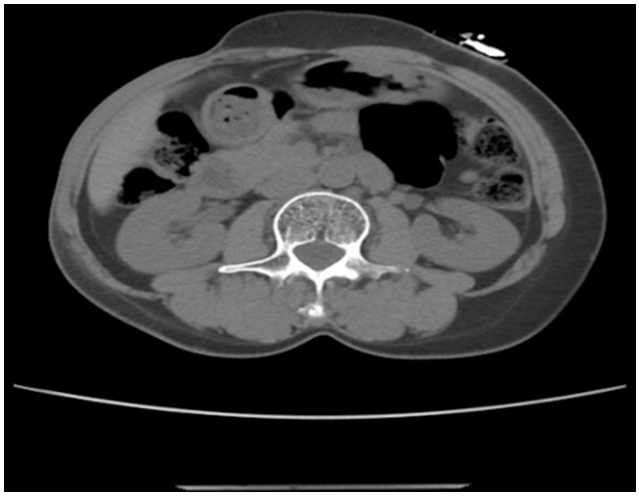

FIGURE 2 CT image of localized lipoatrophy in the right abdomen.

With no apoptotic cells found to be present, apoptosis was ruled out as a mechanism in this case. This patient had no history of metallic allergy, and trauma from metallic needles was thought unlikely as a cause of LL, as she was currently using an SAP for insulin delivery. The patient had no history of comorbidities and no familial predisposition to autoimmune diseases. As one consideration about her developing much less frequent lipoatrophy instead of lipohypertrophy in response to recombinant human insulin, her father had suffered from amyotrophic lateral sclerosis, which may have been associated with her genetic predisposition to lipoatrophy (7). Moreover, although fulminant type 1 diabetes has been classified as idiopathic type 1 diabetes because of the absence of autoimmune markers (1), possible involvement of autoimmunity has been recently reported in this subtype of type 1 diabetes (8). Key findings of note here are that no reduction was seen in adipose cell size even in the depressed areas and that normal-sized adipose cells were shown to be present in the borderline area between depressed and normal areas, suggesting that the LL might be highly reversible.

Worsening of glycemic control in this case was thought to be caused by insulin infusion interruptions and unstable insulin absorption associated with repeated cannula insertions into highly lipoatrophic areas. When the patient was initially converted to SAP therapy, the cannula insertion sites in the right abdomen were less atrophic, with some subcutaneous adipose tissue remaining intact, which made cannula insertions in this area effective, leading to improvements in glycemic control. Subsequent worsening of glycemic control was therefore thought to be caused by frequent cannula insertions into this area, which led to insulin infusion interruptions, making less insulin available for absorption as LL rapidly progressed and involved a wide area, thus contributing to the progressive loss of subcutaneous adipose tissue (9).

The reason the patient had continued to insert cannulas into the depressed areas was that, as she made it a practice to place her glucose sensor on the lower left abdomen and insert cannulas into the lower right, the area available for cannula insertion grew increasingly limited because of the rapid progression of LL to an increasingly wider area. Although checking insulin infusion sites should be a fundamental part of routine diabetes care, it is often overlooked (10).

It is crucially important to treat LL associated with insulin injections not only for cosmetic reasons but also to ensure improved glycemic control (9). Reported treatment approaches to LL include the use of injection site rotation, local steroid injection, insulin vials that also contain steroids, and low-dose oral corticosteroids, but the effects of these approaches vary (11–14). An interventional study found that LL improved in affected patients after switching them from other insulin analogs to insulin glulisine, which, unlike the other available insulin analogs, is free of zinc (15).

In this case, in which the patient's complete insulin deficiency required subcutaneous insulin injections, LL was shown to have progressed rapidly, and subcutaneous biopsies were performed to formulate a treatment plan. Because samples from affected sites showed potential for tissue regeneration, thus obviating the need for steroid treatment, the treatment plan adopted was to replace the patient's insulin analogs with insulin glulisine and to use nonaffected cannula insertion sites in rotation. Indeed, rotating insertion sites led to the resolution of linear, elevated scars, elevation of sagging skin in depressed areas in the lower navel, and a trend for improvement in depressions at the affected sites (Figure 3).

Clinical Pearl

When patients with insulin-dependent diabetes develop LL and experience worsening glycemic control despite SAP therapy, clinicians should review their SAP troubleshooting history and examine their cannula insertion sites to attempt to identify and ameliorate the cause.

DUALITY OF INTEREST

No conflicts of interest relevant to this case presentation were reported.

AUTHOR CONTRIBUTIONS

All authors researched data and wrote and edited the manuscript. K.K. and Y.A. formulated hypotheses, contributed to the discussion, and reviewed the manuscript. Y.A. is the guarantor of this work and, as such, had full access to all of the data in the case study and takes responsibility for the accuracy and integrity of the case presentation.

REFERENCES

1. Imagawa A, Hanafusa T. Fulminant type 1 diabetes: an important subtype in East Asia. Diabetes Metab Res Rev 2011;27:959–964

2. Radermecker RP, Piérard GE, Scheen AJ. Lipodystrophy reactions to insulin: effects of continuous insulin infusion and new insulin analogs. Am J Clin Dermatol 2007;8:21–28

3. Holstein A, Stege H, Kovacs P. Lipoatrophy associated with the use of insulin analogues: a new case associated with the use of insulin glargine and review of the literature. Expert Opin Drug Saf 2010;9:225–231

4. Lopez X, Castells M, Ricker A, Velazquez EF, Mun E, Goldfine AB. Human insulin analog-induced lipoatrophy. Diabetes Care 2008;31:442–444

5. Sackey AH. Images in clinical medicine: injection-site lipoatrophy. N Engl J Med 2009;361:e41

6. Turk Wensveen T, Fučkar Čupić D, Jurišić Eržen D, Polić B, Wensveen FM. Severe lipoatrophy in a patient with type 2 diabetes in response to human insulin analogs glargine and degludec: possible involvement of CD4 T cell-mediated tissue remodeling. Diabetes Care 2020;43:494–496

7. Volkening K, Farhan SMK, Kao J, et al. Evidence of synergism among three genetic variants in a patient with LMNA-related lipodystrophy and amyotrophic lateral sclerosis leading to a remarkable nuclear phenotype. Mol Cell Biochem 2021;476:2633–2650

8. Oikawa Y, Shimada A. Possible involvement of autoimmunity in fulminant type 1 diabetes. Diabetol Int 2020;11:329–335

9. Ma X, Lv H, Li Q, Shen J. Severe lipoatrophy with insulin in type 1 diabetes. J Dermatol 2012;39:578–579

10. Thewjitcharoen Y, Prasartkaew H, Tongsumrit P, et al. Prevalence, risk factors, and clinical characteristics of lipodystrophy in insulin-treated patients with diabetes: an old problem in a new era of modern insulin. Diabetes Metab Syndr Obes 2020;13:4609–4620

11. Kadiyala P, Walton S, Sathyapalan T. Insulin induced lipodystrophy. Br J Diabetes Vasc Dis 2014;14:131–133

12. Ramos AJ, Farias MA. Human insulin-induced lipoatrophy: a successful treatment with glucocorticoid. Diabetes Care 2006;29:926–927

13. Chantelau EA, Praetor R, Praetor J, Poll LW. Relapsing insulin-induced lipoatrophy, cured by prolonged low-dose oral prednisone: a case report. Diabetol Metab Syndr 2011;3:33

14. Breznik V, Kokol R, Luzar B, Miljković J. Insulin-induced localized lipoatrophy. Acta Dermatovenerol Alp Panonica Adriat 2013;22:83–85

15. Kordonouri O, Biester T, Weidemann J, et al. Lipoatrophy in children, adolescents and adults with insulin pump treatment: is there a beneficial effect of insulin glulisine? Pediatr Diabetes 2020;21: 1285–1291