

Clinical and Roentgenological Profiles of Five Patterns of Charcot Foot in Diabetes: A Case Series

Partha P. Chakraborty,¹ Shinjan Patra,¹ Sugata N. Biswas,¹ Gouranga Santra,¹ Satinath Mukhopadhyay,² and Subhankar Chowdhury²

Charcot foot (pied de Charcot) (CF), first described by Jean-Martin Charcot in 1868, is caused by a wide variety of disorders that ultimately destroy the protective mechanisms of the small joints of the foot. Leprosy and diabetes are the most common causes of this form of destructive neuroarthropathy in the developing world. Although the prevalence of Charcot's neuroarthropathy (CN) in diabetes is <0.5% in the Western world (1), we believe the incidence is much higher in our patient population in India. If the diagnosis is missed early in the natural course of the disease, severe foot deformity and disability, ulceration, infection, and ultimately limb amputation are the expected outcomes. Five distinct patterns of involvement have been described in people with diabetes presenting with CF (2). In this article, we share clinical and radiological photographs of each of these subtypes through five case presentations of patients with longstanding diabetes and clinical evidence of advanced peripheral neuropathy in the absence of peripheral vascular disease.

Case Presentations

Case 1

A 71-year-old man with type 2 diabetes presented with swelling of the left great toe and a discharging, nonhealing ulcer on its plantar aspect (Figure 1). Clinical and radiological examinations were suggestive of osteomyelitis of the left great toe. However, we also noticed mid- and

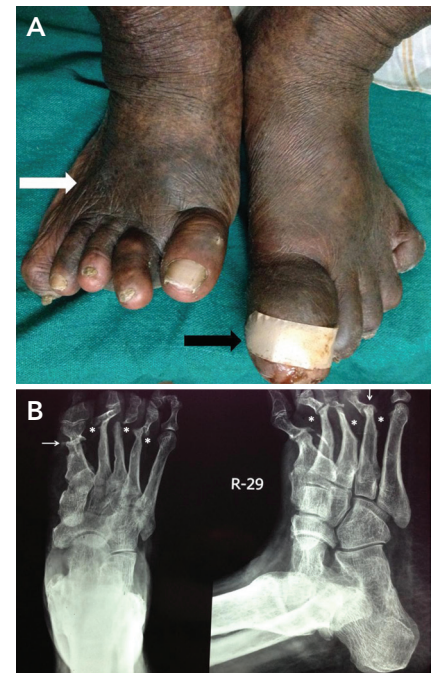


FIGURE 1. Case 1. *A*) Swelling of left great toe with discharging wound (black solid arrow) and right-sided fore-foot widening (white solid arrow). *B*) X-ray of the right foot showing “pencil-in-cup deformity” (white arrow) and “sucked-candy appearance” (*) suggestive of pattern I CF.

forefoot widening on the right side. X-ray of the right foot revealed “pencil-in-cup deformity” involving the first and fourth metatarso-phalangeal (MTP) joints and “sucked-candy appearance” of the second, third, and fourth metatarsals, suggestive of pattern I CF.

Case 2

A 52-year-old man with a 15-year history of type 2 diabetes presented with

¹Department of Medicine, Midnapore Medical College & Hospital, Midnapore, West Bengal, India

²Department of Endocrinology & Metabolism, Institute of Postgraduate Medical Education & Research, IPGME&R/SSKM Hospital, Kolkata, West Bengal, India

Corresponding author: Partha P. Chakraborty, docparthapc@yahoo.co.in

DOI: 10.2337/cd15-0047

©2016 by the American Diabetes Association. Readers may use this article as long as the work is properly cited, the use is educational and not for profit, and the work is not altered. See <http://creativecommons.org/licenses/by-nc-nd/3.0> for details.

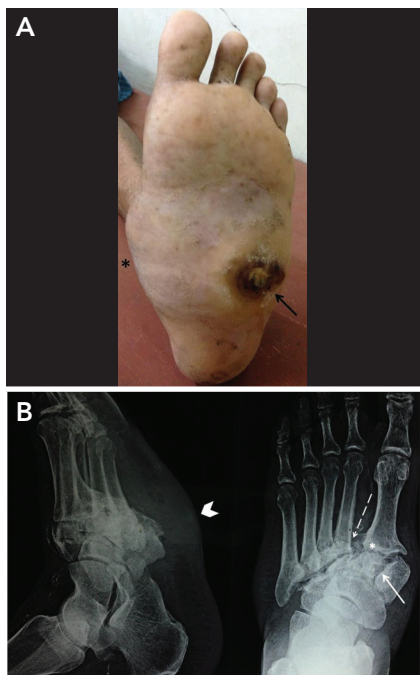


FIGURE 2. Case 2. *A*) Rocker-bottom deformity of the left foot (*) with midfoot plantar ulcer (arrow). *B*) X-ray showing fracture of the medial cuneiform (right side, solid arrow), lateral displacement of the second metatarsal base (right side, dashed arrow), and destruction of the tarso-metatarsal joints (*), suggestive of pattern II CF. The arrowhead (left side) denotes rocker-bottom deformity of the foot.

progressive left foot deformity for 6 months after a trivial trauma and subsequent development of a nonhealing ulcer over the midfoot for the past 3 months. Patient had rocker-bottom deformity of his left foot with a nonhealing ulcer (Figure 2). X-ray of his left foot revealed fracture of the medial cuneiform, lateral displacement of the second metatarsal base, and destruction of the tarso-metatarsal (TM) joints, suggestive of pattern II CF.

Case 3

A 65-year-old man with type 2 diabetes presented with an infected ulcer over the dorsum of his left foot. Features of inflammation were evident on local examination, along with the presence of bony crepitations. The ulcer healed significantly after

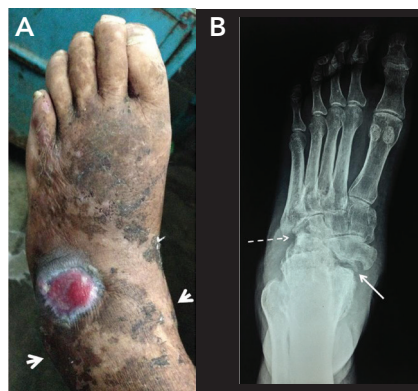

FIGURE 3. Case 3. *A*) Widening of the ankle mortise (between arrowheads) and midfoot with partially healed dorsal ulcer. *B*) X-ray showing involvement of talo-navicular (solid arrow) and calcaneo-cuboid joints (dashed arrow), suggestive of pattern III CF.

4 weeks of appropriate antibiotics (Figure 3). X-ray showed involvement of talo-navicular and calcaneo-cuboid joints, suggestive of pattern III CF. There was no radiological suggestion of osteomyelitis.

Case 4

A 31-year-old woman with long-standing poorly controlled type 1 diabetes came to us with a nonhealing hind foot ulcer involving her left foot (Figure 4). The lateral longitudinal arch of the foot was lost, resulting in rocker-bottom deformity. X-ray of the left foot was suggestive of combined pattern IV (involvement of the subtalar joints) and pattern II (involvement of the tarso-metatarsal joints) CF.

Case 5

A 45-year-old man with poorly controlled diabetes presented with a discharging ulcer on the lateral aspect his left hind foot. There was significant swelling of the entire left foot with minimal pain. He denied sustaining any form of major or minor trauma to his left foot. Culture of the tissue bits obtained from the deeper aspect of the ulcer grew Klebsiella species. After 6 weeks of appropriate antibiotics and off-loading, the ulcer healed completely, but there was minimal improvement in the swelling (Figure 5).

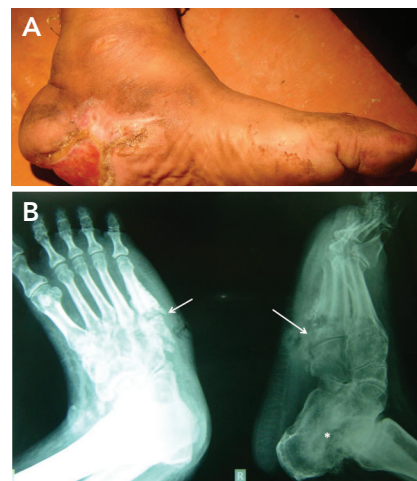


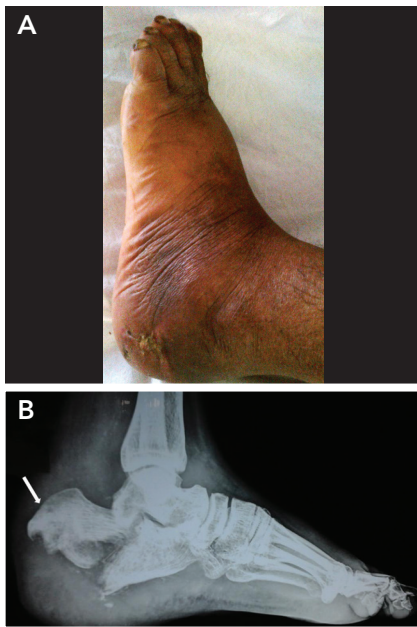
FIGURE 4. Case 4. *A*) Nonhealing ulcer over left hind foot, with loss of lateral longitudinal arch (marked by arrowheads). *B*) X-ray of the left foot, with involvement of subtalar joints (*) and involvement of the tarso-metatarsal joints (arrows), suggestive of combined pattern IV and pattern II CF.

We also noticed an abnormal range of motion of the left ankle joint and bony crepitations around the heel. X-ray of the foot revealed a fracture of the calcaneum with posterior and superior displacement of the fragment. Subsequent MRI of the foot documented abnormal bone marrow signals from calcaneum, talus, and other tarsal bones. A diagnosis of pattern V CF was considered.

All five of these patients were treated conservatively. Initially, their infections were controlled with appropriate antibiotics based on culture sensitivity. After making the wounds sterile, initial off-loading was done with a total contact cast (TCC). The TCCs were removed every week, the injured feet were inspected, and new TCCs were advised until the temperature difference between the two feet became negligible, after which customized footwear was advised.

Questions

1. What is Charcot's neuroarthropathy?
2. What is the underlying mechanism of Charcot's neuroarthropathy?



■ **FIGURE 5.** Case 5. *A)* Swollen left foot with healed ulcer over the lateral aspect of the hind foot. *B)* Lateral X-ray of the foot showing calcaneal fracture and posterior and superior displacement of the fragment (arrow), compatible with pattern V CF.

3. What are the stages of Charcot's neuroarthropathy?
4. What are the patterns of Charcot's neuroarthropathy in the diabetic foot?
5. What are the radiological findings in each of the patterns?
6. What is the appropriate management of Charcot's neuroarthropathy?

Commentary

CN usually has an insidious onset and a progressive course marked by bone destruction and bone resorption, followed by sclerosis and gradually worsening deformity. Although the exact etiology remains largely unknown, two primary hypotheses have been put forward: the neuro-traumatic hypothesis (3) and the neurovascular hypothesis (4). Peripheral neuropathy with or without autonomic neuropathy is the single most important predisposing factor of CN.

Decades ago, Eichenholtz (5) offered a staging system based on the natural history of the joint destruc-

tion process: stage 0 (prodromal period), stage 1 (development stage), stage 2 (coalescence stage), and stage 3 (reconstruction stage). Plain radiographs are most often normal in stage 0, when the disease can be picked up by MRI or skeletal scintigraphy. X-ray evidence of CN becomes prominent from stage 1 on, and this stage is also known as “acute Charcot.” Roentgenologically, two types of abnormality have been recognized: atrophic (involving osteolysis of the distal metatarsals) and the more common hypertrophic joint disease. Yochum and Rowe (6) described the “6 Ds” of the hypertrophic form: distended joint, increased density, debris, dislocation, disorganization, and destruction.

Five separate anatomic patterns (I–V) of CN involving different joints in patients with diabetes:

- Pattern I: Involvement of the forefoot joints (interphalangeal and MTP joints) and bones (phalanges and distal metatarsals). The characteristic plain radiographic appearance of the pattern includes an “hourglass” appearance of the phalangeal diaphysis and a pencil-like tapering of the distal metatarsals with a “sucked candy stick” appearance and broadening of the bases of the proximal phalanges to form a cup around the pencil-like metatarsal heads—the so-called “pencil-in-cup” appearance.
- Pattern II: Involvement of the TM (Lisfranc) joints with resultant rocker-bottom foot deformity caused by the total disintegration of the cuneiforms and collapse of the midfoot.
- Pattern III: Dislocation and fracture of the midtarsal joints such as the naviculo-cuneiform, talo-navicular, and calcaneo-cuboid joints.
- Pattern IV: Involvement of ankle and/or subtalar joints.
- Pattern V: Involvement of calcaneus, which may be seen as an isolated fracture of the calcaneus

or with involvement of other tarsal bones. These fractures are mostly nontraumatic, limited to the posterior third of the bone, and identical to the calcaneal fatigue fracture, with displacement and rotation of the posterior tuberosity. Kathol et al. (7) coined the term “calcaneal insufficiency avulsion fracture” to describe this unique entity. The avulsed fragment of the calcaneum is displaced superiorly because of the constant pull of tendoachilles, which was evident in case 5.

These patterns can be present in isolation or in combination. One of our patients (case 4) had combined pattern IV and pattern II CF. Among these patterns, II and III are the most commonly encountered, followed by pattern I, whereas pattern V is the least common form. Patterns I and II are frequently associated with bony deformities and ulcerations, which are considered the cutaneous marker of these forms of CF. Patients described as case 2 and case 4 presented with rocker-bottom deformity and nonhealing plantar ulcers, typical of pattern II CF. The most severe forms of structural deformity and functional instability are seen in patterns II and IV, which were evident in case 4.

The cornerstone of management in all stages of CF is effective off-loading of the involved foot, which can be accomplished with customized footwear or various removable or irremovable off-loading devices. Infection, if present, should be treated with appropriate antibiotics. The early stages of CF—the so-called “acute Charcot foot”—may be missed or misdiagnosed if the diagnosis is not considered in patients presenting with a warm, swollen foot. Different thermometers are available to identify subtle differences in surface temperature between two feet and are useful for screening patients in a busy clinic setting. If CF is diagnosed in the acute phase, a

single intravenous infusion of 90 mg pamidronate or weekly oral administration of 70 mg alendronate for 6 months has been shown to be associated with significant improvement in symptoms, bone turnover markers, and foot bone density (8,9).

Clinical Pearls

- CF is not uncommon in patients with longstanding diabetes in the developing world.
- It is underdiagnosed and hence underreported.
- Plain radiology of the foot is an inexpensive and effective way to diagnose many patients with CF.
- X-ray of the foot should be advised in all patients with diabetes presenting with subtle foot deformities to diagnose underlying CF.
- Health care providers should be

aware of the different patterns of CF because early recognition and subsequent immobilization is the cornerstone of successful management.

Duality of Interest

No potential conflicts of interest relevant to this article were reported.

References

1. Hartemann-Heurtier A, Van GH, Grimaldi A. The Charcot foot. *Lancet* 2002;360:1776–1779
2. Sanders LJ, Frykberg RG. Charcot neuroarthropathy of the foot. In *Levin and O’Neal’s The Diabetic Foot*. 7th ed. Bowker JH, Pfeifer MA, Eds. St Louis, MO, Mosby, 2008, p. 257–286
3. Jeffcoate WJ, Game F, Cavanagh PR. The role of proinflammatory cytokines in the cause of neuropathic osteoarthropathy (acute Charcot foot) in diabetes. *Lancet* 2005;366:2058–2061

4. Chantelau E, Richter A, Ghassem-Zadeh N, Poll LW. “Silent” bone stress injuries in the feet of diabetic patients with polyneuropathy: a report on 12 cases. *Arch Orthop Trauma Surg* 2007;127:171–177
5. Eichenholtz SN. *Charcot Joints*. Springfield, IL, Thomas, 1966
6. Yochum T, Rowe L. Neuropathic arthropathy. In *Essentials of Skeletal Radiology*. 2nd ed. Yochum T, Rowe L, Eds. Baltimore, MD, William & Wilkins, 1987, p. 842–849
7. Kathol MH, el-Khoury GY, Moore TE, Marsh JL. Calcaneal insufficiency avulsion fractures in patients with diabetes mellitus. *Radiology* 1991;180:725–729
8. Jude EB, Selby PL, Burgess J, et al. Bisphosphonates in the treatment of Charcot neuroarthropathy: a double-blind, randomised controlled trial. *Diabetologia* 2001;44:2032–2037
9. Pitocco D, Ruotolo V, Caputo S, et al. Six-month treatment with alendronate in acute Charcot neuroarthropathy: a randomized controlled trial. *Diabetes Care* 2005;28:1214–1215