

Expression of Mesenchymal and α -Cell Phenotypic Markers in Islet β -Cells in Recently Diagnosed Diabetes

MICHAEL G. WHITE, MRES¹
HELEN L. MARSHALL, PHD¹
REBECCA RIGBY, BSC¹
GUO CAI HUANG, PHD²

AIMEN AMER, FRCS¹
TREVOR BOOTH, PHD¹
STEVE WHITE, FRCS¹
JAMES A.M. SHAW, FRCP, PHD¹

OBJECTIVE—Relative contributions of reversible β -cell dysfunction and true decrease in β -cell mass in type 2 diabetes remain unclear. Definitive rodent lineage-tracing studies have identified β -cell dedifferentiation and subsequent reprogramming to α -cell fate as a novel mechanism underlying β -cell failure. The aim was to determine whether phenotypes of β -cell dedifferentiation and plasticity are present in human diabetes.

RESEARCH DESIGN AND METHODS—Immunofluorescence colocalization studies using classical endocrine and mesenchymal phenotypic markers were undertaken using pancreatic sections and isolated islets from three individuals with diabetes and five nondiabetic control subjects.

RESULTS—Intra-islet cytoplasmic coexpression of insulin and vimentin, insulin and glucagon, and vimentin and glucagon were demonstrated in all cases. These phenotypes were not present in nondiabetic control subjects.

CONCLUSIONS—Coexpression of mesenchymal and α -cell phenotypic markers in human diabetic islet β -cells has been confirmed, providing circumstantial evidence for β -cell dedifferentiation and possible reprogramming to α -cells in clinical diabetes.

Diabetes Care 36:3818–3820, 2013

The relative contribution of reversible β -cell dysfunction and a true decrease in β -cell mass during the onset of and progression of type 2 diabetes have been hotly debated (1,2). Modest decreases in numbers of β -cells per islet and increases in β -cell apoptosis have been reported (3), but whether these are sufficient to account for the reduction in insulin secretory capacity remains unclear (4). Underpinned by recent rodent studies (5), a new hypothesis has been proposed whereby β -cell failure and increased α -cell function occur through dedifferentiation and reprogramming (6). We report, for the first time, expression of mesenchymal and α -cell phenotypic markers in human β -cells

within intact islets of three individuals with diabetes.

RESEARCH DESIGN AND METHODS

Ethical approval was acquired and informed consent was obtained from the patient or the family of the patient. In addition to patient samples, control pancreatic blocks and isolated islet sections were prepared from five deceased donors without diabetes (three women; age 24–61 years; BMI 25–34 kg/m²).

Tissue blocks and isolated islets were fixed in formalin and embedded in paraffin. Sections were stained with hematoxylin and eosin in addition to Sirius Red collagen staining using standard procedures.

Indirect immunofluorescence staining was performed on 4- μ m sections after deparaffinization, rehydration, and heat-mediated antigen retrieval using citrate buffer. After blocking with 10% FCS, sections were incubated with guinea pig anti-insulin (1:500; Abcam, Cambridge, U.K.), rabbit antivimentin (1:250; Abcam), or mouse antiglucagon (1:1,000; Sigma-Aldrich, Gillingham, U.K.) overnight. Sections were incubated with anti-guinea pig fluorescein isothiocyanate, anti-mouse AF543, or anti-rabbit AF488/AF543 secondary antibodies (Invitrogen, Paisley, U.K.). For negative control subjects, primary antibody was replaced with appropriate serum. All sections were counterstained with 4',6-diamidino-2-phenylindole.

RESULTS

Case reports

Patient 1 was a 65-year-old woman whose pancreas was procured during deceased organ donation after brain death after intracranial hemorrhage. Type 2 diabetes was diagnosed 15 months before death and was treated with metformin. Comorbid hypertension was treated with ramipril and hyperlipidemia was treated with simvastatin. BMI was 32 kg/m², with random plasma glucose of 8.1 mmol/L.

Patient 2 was an 81-year-old woman who underwent distal pancreatectomy for an intraductal papillary mucinous neoplasm. She had experienced two episodes of pancreatitis 12 months and 7 years before pancreatic resection but had no chronic symptoms or evidence of pancreatic exocrine deficiency. Diabetes was diagnosed 17 months before surgery and treated with metformin. There were no other comorbidities and BMI was 25 kg/m². Random plasma glucose was 7.5 mmol/L with HbA_{1c} of 72 mmol/mol (HbA_{1c} 8.7%).

Patient 3 was a 52-year-old woman whose pancreas was procured for clinical islet isolation during deceased organ donation after brain death after intracranial hemorrhage. There was no history of known diabetes, but a diagnostic HbA_{1c} test performed on admission indicated HbA_{1c} of

From the ¹Institute of Cellular Medicine and North East Stem Cell Institute, Newcastle University, Newcastle upon Tyne, U.K.; and the ²Diabetes Research Group, King's College London, London, U.K.

Corresponding author: James A.M. Shaw, jim.shaw@ncl.ac.uk.

Received 24 March 2013 and accepted 10 June 2013.

DOI: 10.2337/dc13-0705

This article contains Supplementary Data online at <http://care.diabetesjournals.org/lookup/suppl/doi:10.2337/dc13-0705/-/DC1>.

M.G.W. and H.L.M. contributed equally to experimental design, completion, analysis, and manuscript preparation.

© 2013 by the American Diabetes Association. Readers may use this article as long as the work is properly cited, the use is educational and not for profit, and the work is not altered. See <http://creativecommons.org/licenses/by-nc-nd/3.0/> for details.

63 mmol/mol (HbA_{1c} 7.9%) with random glucose of 8.7 mmol/L. There were no other comorbidities, and BMI was 25 kg/m².

Patient 1. Morphological analysis after hematoxylin and eosin staining of pancreatic sections showed islet size, distribution, and integrity comparable with those of nondiabetic control subjects. There was no overt islet inflammatory cell infiltration in patient or control sections. There was no evidence of fibrosis in islets or exocrine pancreatic tissue with patterns of collagen deposition comparable with those of control samples on Sirius Red staining.

Immunofluorescence staining clearly demonstrated cells within intact islets expressing both insulin and vimentin in the cytoplasm. Representative images from the pancreatic tail are shown in Fig. 1A–D. As shown, cells expressing insulin and vimentin were present in ~40% of islets, constituting ~5% of insulin-positive cells in affected islets. In cells expressing both phenotypic markers, confocal imaging confirmed coexpression within individual cells and maintained characteristic cytoplasmic insulin and filamentous vimentin staining patterns.

In contrast, no coexpression of vimentin in insulin-positive cells within or outside islets was detected in nondiabetic control sections. Cytofluorograms confirmed colocalization of both markers in patient 1 (Fig. 1E) but confirmed absence of this mixed phenotype in control sections (Fig. 1F).

Islet cells coexpressing insulin and glucagon within the cytoplasm were identified in pancreatic sections from patient 1 (Fig. 1G–I). Coexpression of vimentin within glucagon-positive cells also was confirmed (Fig. 1J–L). Both of these phenotypes were rare, constituting ~1% of all islet cells. In contrast, neither of these mixed phenotypes could be detected on pancreatic sections from nondiabetic control subjects.

Patient 2. Macroscopic examination of resected pancreatic tail demonstrated a cystic area with a maximum diameter of 8 mm. Staining of pancreatic sections confirmed intraductal papillary mucinous neoplasm without high-grade dysplasia or evidence of malignancy. There was evidence of lobular atrophy and granulomatous inflammation in the surrounding pancreas, but islet endocrine morphology was reported as being within normal limits.

Islets stained positive for insulin, with categorical evidence of cells coexpressing insulin and vimentin, insulin and glucagon, and vimentin and glucagon

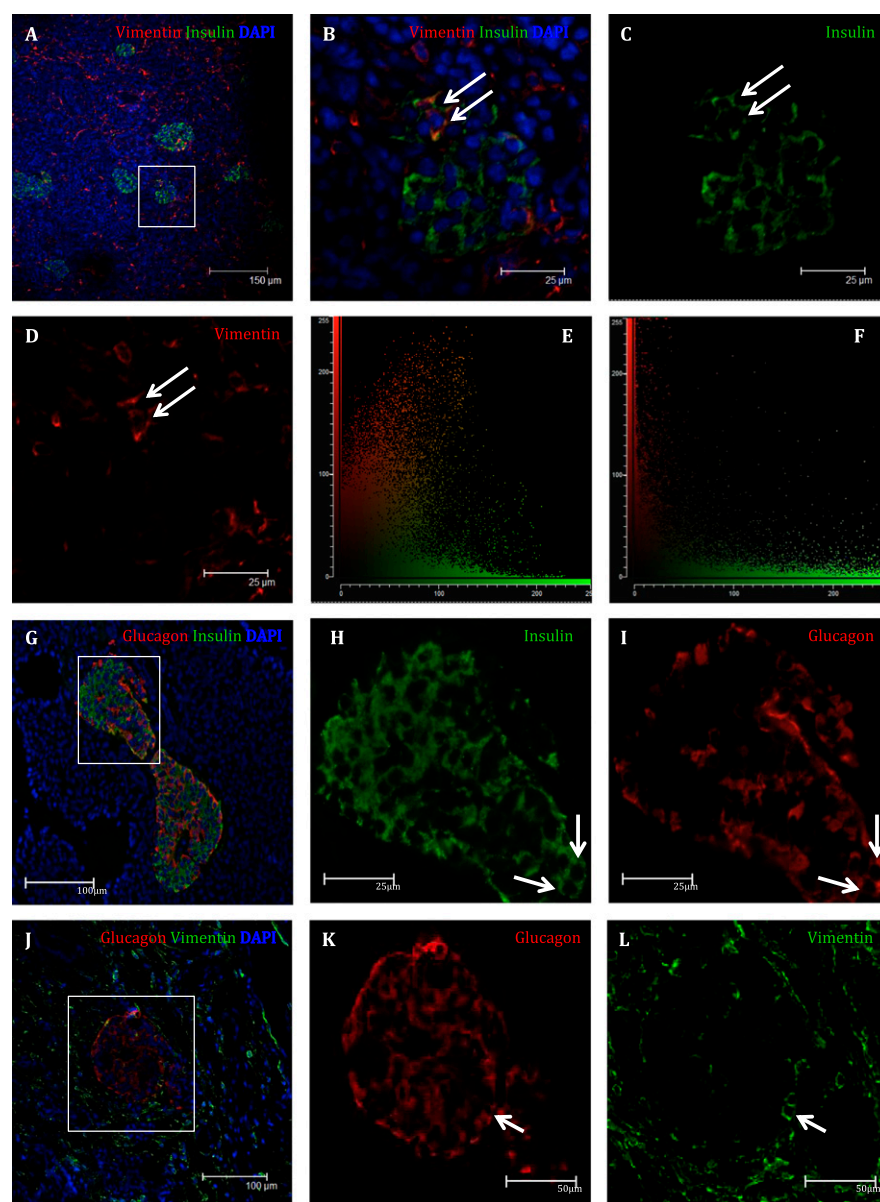


Figure 1—Pancreatic phenotypic analysis of patient 1. Intraislet β -cells coexpressing the mesenchymal marker vimentin (A–D). The boxed area in panel A indicates the region that is magnified in panels B–D. Arrows indicate cells expressing both insulin (B,C) and vimentin (B,D). E: Cytofluorogram derived from this image confirming colocalization of insulin and vimentin in islet β -cells. Comparative cytofluorogram from stained, normal, nondiabetic pancreas (F) confirming no colocalization of insulin (green) and vimentin (red). G–I: Representative images show islet β -cells from patient 1 coexpressing the α -cell marker glucagon. The boxed area in panel G indicates the magnified region in panels H and I, with arrows indicating cells expressing both insulin (H) and glucagon (I). J–L: Intraislet cells coexpressing glucagon and vimentin. The boxed area in panel J indicates the region that is magnified in panels K and L. Arrows indicate cells expressing both glucagon (K) and vimentin (L).

(Supplementary Fig. 1) within the cytoplasm. As in patient 1, ~5% of insulin-positive cells in affected islets coexpressed insulin and vimentin. In patient 2, although cells expressing only insulin, glucagon, or vimentin could be clearly identified, many cells coexpressed insulin and glucagon and vimentin and glucagon in virtually all islets.

Patient 3. Immunofluorescence staining of isolated islets enabled clear differentiation of individual cells, particularly at the periphery. Cells coexpressing insulin and vimentin, insulin and glucagon, and vimentin and glucagon within the cytoplasm were identified (Supplementary Fig. 2). Absence of any of these phenotypes

in control islets isolated from nondiabetic donors was confirmed.

CONCLUSIONS—Consistent with a role for dedifferentiation in the pathogenesis of β -cell dysfunction in diabetes, we describe previously unreported coexpression of mesenchymal and α -cell phenotypic markers in insulin-positive cells in two patients with recently diagnosed noninsulin-requiring diabetes and in one patient with previously undiagnosed diabetes. Furthermore, coexpression of vimentin in islet glucagon-positive cells has been demonstrated.

It recently has been postulated from a series of β -cell fate-marking studies of transgenic mice that dedifferentiation is the primary mechanism underlying β -cell failure in nonautoimmune diabetes (5). Specifically, the investigators proposed that metabolic stress leads to activation of mesenchymal markers in endocrine cells, a phenomenon well described in human β -cells after establishment in adherent proliferative culture but not previously described in vivo in preclinical studies or in situ in humans (7,8).

The lineage-tracing studies performed by Talchai et al. (5) demonstrated that a number of dedifferentiated β -cells undergo conversion to other endocrine phenotypes, leading them to suggest that β -cell reprogramming to α -cells may explain the apparent reciprocal association of insulinopenia with hyperglucagonemia in early type 2 diabetes (9). The presence of cells coexpressing glucagon and insulin in the patients reported here is in keeping with this hypothesis. We also detected cells expressing both glucagon and vimentin, a phenotype reported in the preclinical studies. Dedifferentiation of nonendocrine pancreas with

coexpression of epithelial and mesenchymal markers has been recognized in human sections, with occasional cells coexpressing vimentin and glucagon within the ducts of patients with type 2 diabetes (10).

Our data provide circumstantial evidence for the recently reported phenomenon of β -cell dedifferentiation and possible reprogramming to α -cells in humans. Whether this process is reversible in vivo, contributing to the rapid recovery of β -cell function after calorie restriction or bariatric surgery, requires further study. If so, then this may provide a new target for the development of disease-modifying drugs that restore β -cell mass and function in type 2 and secondary diabetes through redifferentiation.

Acknowledgments—This study was funded by Diabetes UK. All laboratory work was performed at the Institute of Cellular Medicine, Newcastle University.

No potential conflicts of interest relevant to this article were reported.

Diabetes UK had no role in the design, data collection, interpretation, writing the report, or decision to submit the manuscript for publication.

M.G.W. and H.L.M. designed the study; were involved with laboratory investigations, data collection, and analysis; and contributed equally to manuscript preparation. R.R. and T.B. were involved in data collection and analysis. G.C.H. performed clinical-grade islet isolation for the studies within the King's College London designated good manufacturing practice facility. A.A. and S.W. procured human tissue for studies. J.A.M.S. approved the finalized manuscript. J.A.M.S. is the guarantor of this work and, as such, had full access to all the data in the study and takes responsibility for the integrity of the data and the accuracy of the data analysis.

This work was performed in partial fulfillment of the requirements for a PhD degree for M.G.W.

The authors thank Diabetes UK for funding and support throughout the duration of this study.

References

1. Accili D. Lilly lecture 2003: the struggle for mastery in insulin action: from triumvirate to republic. *Diabetes* 2004;53:1633–1642
2. Cnop M, Igoillo-Estevé M, Hughes SJ, Walker JN, Cnop I, Clark A. Longevity of human islet α - and β -cells. *Diabetes Obes Metab* 2011;13(Suppl. 1):39–46
3. Butler AE, Janson J, Bonner-Weir S, Ritzel R, Rizza RA, Butler PC. β -cell deficit and increased β -cell apoptosis in humans with type 2 diabetes. *Diabetes* 2003;52:102–110
4. Butler PC, Meier JJ, Butler AE, Bhushan A. The replication of beta cells in normal physiology, in disease and for therapy. *Nat Clin Pract Endocrinol Metab* 2007;3:758–768
5. Talchai C, Xuan S, Lin HV, Sussel L, Accili D. Pancreatic β cell dedifferentiation as a mechanism of diabetic β cell failure. *Cell* 2012;150:1223–1234
6. Dor Y, Glaser B. β -cell dedifferentiation and type 2 diabetes. *N Engl J Med* 2013;368:572–573
7. Gershengorn MC, Hardikar AA, Wei C, Geras-Raaka E, Marcus-Samuels B, Raaka BM. Epithelial-to-mesenchymal transition generates proliferative human islet precursor cells. *Science* 2004;306:2261–2264
8. Russ HA, Sintov E, Anker-Kitai L, et al. Insulin-producing cells generated from dedifferentiated human pancreatic beta cells expanded in vitro. *PLoS ONE* 2011;6:e25566
9. Dunning BE, Gerich JE. The role of alpha-cell dysregulation in fasting and postprandial hyperglycemia in type 2 diabetes and therapeutic implications. *Endocr Rev* 2007;28:253–283
10. Fanjul M, Gmyr V, Sengenès C, et al. Evidence for epithelial-mesenchymal transition in adult human pancreatic exocrine cells. *J Histochem Cytochem* 2010;58:807–823