

Retinal Vascular Changes in Pre-Diabetes and Prehypertension

New findings and their research and clinical implications

THANH TAN NGUYEN, MBBS¹
JIE JIN WANG, MMED, PHD^{1,2}
TIEN YIN WONG, MD, PHD^{1,3}

The retinal vasculature can be viewed directly and noninvasively, offering a unique and easily accessible “window” to study the health and disease of the human microcirculation in vivo. In the last decade, advances in digital retinal photography and imaging techniques have allowed precise characterization of subtle retinal vascular changes in large populations. These retinal changes can be broadly divided into four groups: 1) classic retinal vascular changes in diabetes and hypertension (i.e., diabetic and hypertensive retinopathy), 2) isolated retinopathy signs in individuals with diabetes or hypertension (e.g., microaneurysm, retinal hemorrhage, or cotton wool spot), 3) changes in retinal vascular caliber, and 4) changes in retinal vascular architecture (e.g., retinal tortuosity).

New studies in large populations now show that retinal vascular changes are common in the general population and may precede the subsequent development of overt diabetes and hypertension. A consistent pattern of associations is also emerging, showing that specific retinal vascular changes may be related differently to hyperglycemia and blood pressure.

In this review, we summarize recent studies on the retinal vascular changes seen in diabetes and hypertension and speculate on potential research and clinical implications.

CLASSIC RETINAL VASCULAR CHANGES

Diabetic retinopathy

In individuals with diabetes, the classic primary retinal vascular complication—diabetic retinopathy—is well described (1). Diabetic retinopathy signs are broadly divided into nonproliferative and proliferative retinopathy. The prevalence of diabetic retinopathy increases with duration of diabetes. The Australian Diabetes, Obesity and Lifestyle Study (Aus-Diab) showed that the prevalence of diabetic retinopathy is less than 10% in those with diabetes duration of less than 5 years but more than 50% in those with 20 years or longer diabetes (2). The two major risk factors of diabetic retinopathy are hyperglycemia and hypertension, with hyperlipidemia as a possible third major risk factor. The importance of hyperglycemia has been confirmed in epidemiological studies (3), as well as two pivotal clinical trials: the DCCT (Diabetes Control and Complications Trial) in patients with type 1 diabetes (4) and the UKPDS (UK Prospective Diabetes Study) in patients with type 2 diabetes (5). The UKPDS also showed that blood pressure control reduces the risk of retinopathy independent of glycemia levels (6). New data from the FIELD (Fenofibrate Intervention and Event Lowering in Diabetes) Study now suggest that lipid-lowering

therapy may also reduce retinopathy requiring laser treatment (7).

Hypertensive retinopathy

Like diabetic retinopathy, classic hypertensive retinopathy is well characterized. The clinical signs include generalized and focal arteriolar narrowing, arterio-venous nicking, increased retinal arteriolar light reflex (copper or silver wiring), flame- and blot-shaped retinal hemorrhages, cotton wool spots, and, in severe cases, optic disc swelling (8,9). The association of these retinal signs with blood pressure is consistent and seen in both adults (10–20) and children (21), even in individuals without clinical hypertension (13–15, 22–24).

ADVANCES IN ASSESSING RETINAL VASCULAR CHANGES

Digital retinal photography and new imaging technology have now allowed more precise assessment of the subtle changes seen in the retinal microvasculature (22,25–28). One key development has been methods to objectively quantify retinal vascular caliber. Historically, narrowed retinal arteriolar caliber, an early hypertensive retinopathy sign, has been difficult to measure using the clinical ophthalmoscope (29). Parr, Hubbard, and colleagues (22,30,31) developed techniques to measure retinal vascular caliber from photographs and summarized these as the arterio-venous ratio (AVR). These techniques are now used in large epidemiological studies (20,22,25,27,28) and have substantial reproducibility.

Recent studies suggest the interpretation of the AVR may be overly simplistic. A smaller AVR was thought to reflect generalized retinal arteriolar narrowing, since venular caliber was assumed to be relatively constant (22). Thus, when a low AVR was associated with elevated blood pressure (18,32) and cardiovascular outcomes such as stroke (33,34) and coronary heart disease (35), the associations were initially thought to reflect generalized arteriolar narrowing. Newer analyses, however, suggest a smaller AVR may

From the ¹Centre for Eye Research Australia, University of Melbourne, Victoria, Australia; the ²Centre for Vision Research, University of Sydney, New South Wales, Australia; and the ³Singapore Eye Research Institute, National University of Singapore, Singapore.

Address correspondence and reprint requests to Tien Yin Wong, MD, PhD, Centre for Eye Research Australia, University of Melbourne, 32 Gisborne St., Victoria 3002, Australia. E-mail: twong@unimelb.edu.au.

Received for publication 15 April 2007 and accepted in revised form 20 June 2007.

Published ahead of print at <http://care.diabetesjournals.org> on 26 June 2007. DOI: 10.2337/dc07-0732.

Abbreviations: ARIC, Atherosclerosis Risk In Communities; AVR, arterio-venous ratio.

A table elsewhere in this issue shows conventional and Système International (SI) units and conversion factors for many substances.

© 2007 by the American Diabetes Association.

not only reflect narrower arterioles but also wider venules (36,37). Furthermore, arteriolar and venular calibers appear to reflect different pathophysiological processes (37,38).

Liew et al. (38,39) have suggested the need to control for venular caliber in statistical models of arteriolar caliber, and vice versa, as venular caliber explains ~30% of the variability in arteriolar caliber (38)—presumably from shared genetic and ocular factors (22).

Improvements in imaging software have also led to quantification of other architectural changes in the retinal vascular network (36,37), as well as “batch processing” of retinal images (20,22, 25,27,28). There remain technical challenges. For example, the impact of magnification error (i.e., eyes of different refraction) requires further study (40).

ISOLATED RETINOPATHY SIGNS

Epidemiology

There is increasing evidence that typical lesions of diabetic retinopathy (microaneurysms, hemorrhages, and cotton wool spots), termed isolated retinopathy signs, are now recognized to be more common than previously thought in people without diabetes and hypertension (41–43). Recent studies using retinal photography to document these signs suggest prevalence rates in the general population of 5–10% (2,13–15,22–24,44) (Fig. 1A) and 2.6–8.6% among those without diabetes or hypertension (13–15,22–24) (Fig. 1B). Prospective study data have further shown that up to 10% of individuals aged ≥40 years without diabetes may develop these isolated retinopathy signs within 5 years (16,45).

Two studies have reported on the prevalence of retinopathy in individuals with pre-diabetes. In the AusDiab Study, retinopathy signs were seen in 6.7% of individuals with impaired glucose tolerance or impaired fasting glucose (46), whereas in the Diabetes Prevention Program this was seen in 7.9% of individuals with impaired fasting glucose (5.3–6.9 mmol/l) or impaired glucose tolerance, who had no history of diabetes (47).

These isolated retinopathy signs may be transient. Population studies show that between 40 and 70% of these isolated retinopathy signs seen at baseline are not present 3–5 years later (45,48).

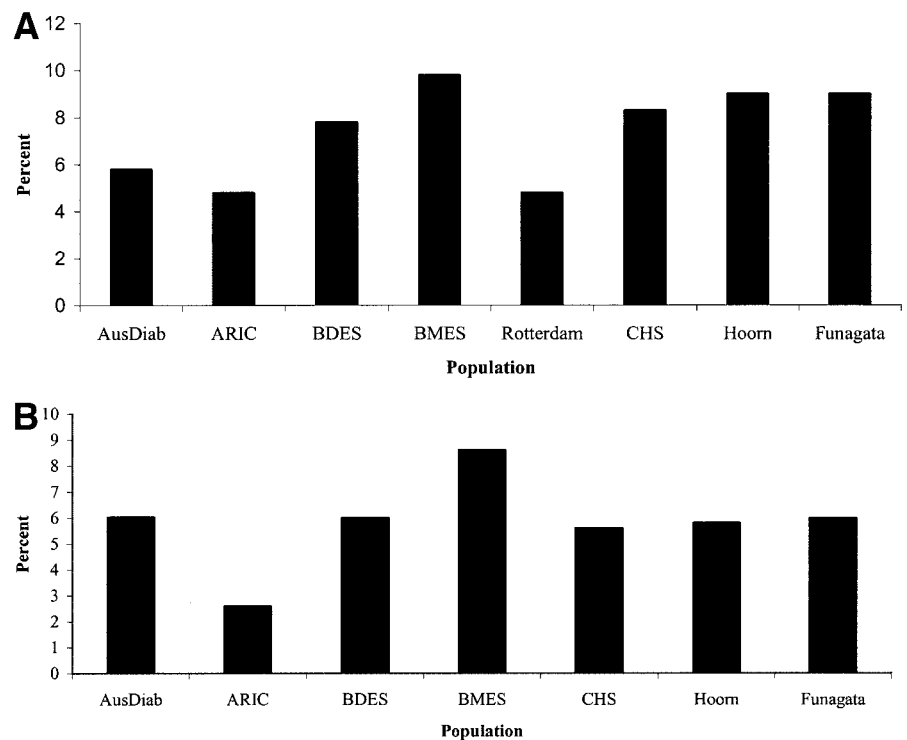


Figure 1—Prevalence of retinopathy in nondiabetic populations (A) and nondiabetic and nonhypertensive populations (B). AusDiab: Australian Diabetes, Obesity and Lifestyle Study (year began: 1999–2000, n = 2,177, aged ≥25 years) (2); ARIC (year began: 1987–1990, n = 10,954, aged 48–73 years) (22); BDES: Beaver Dam Eye Study (year began: 1988–1990, n = 4,926, aged 43–84 years) (15); BMES: Blue Mountain Eye Study (year began: 1992–1994, n = 3,654, aged 49–97 years) (13); CHS: Cardiovascular Health Study (year began: 1989–1990, n = 2,050, aged 67–97 years) (14); Hoorn (year began: 1989–1992, n = 626, aged 50–74 years) (23); Rotterdam (year began: 1990–1993, n = 6,191, aged 55–99 years) (44), and Funagata (year began: 2000–2002, n = 1,481, aged ≥35 years) (24).

Risk factors and pathophysiology

The underlying risk factors and pathophysiology of isolated retinopathy signs in nondiabetic and normotensive individuals are poorly understood. Associations of these retinopathy signs with increasing age (15,45), elevated blood pressure (8,13–15,44,47–49), and hyperglycemia (24,44,47,48) have been found. Other possible risk factors include hyperlipidemia (17,23,48), higher BMI (23,24), and systemic inflammation (48,50). We can speculate that isolated retinopathy signs in normotensive and nondiabetic individuals may represent early microvascular damage from a combination of risk factors, including blood pressure and abnormal glucose metabolism, which may reflect an underlying process of developing clinical diabetes or hypertension.

Animal models and human studies suggest that chronic inflammation and glucose-induced arteriolar endothelial dysfunction are related to development of classic diabetic retinopathy (51–53). The association of inflammation and signs of

isolated retinopathy in people without diabetes (50) supports the hypothesis that inflammatory processes may also be a possible pathway that underlies early subclinical microvascular disease in the pre-diabetes or prehypertension state.

Associations with risk of diabetes, hypertension, and cardiovascular diseases

A clinically relevant question is whether signs of isolated retinopathy in individuals without diabetes are markers of the future risk of diabetes (i.e., do these patients require monitoring for the development of diabetes). The evidence here is not consistent. While previous studies suggest that detectable retinopathy precedes the onset of type 2 diabetes by 4–7 years (54), new prospective data from the Blue Mountains (45,55), the Atherosclerosis Risk In Communities (ARIC) (56), and Beaver Dam (57) studies reported no increased risk of diabetes in nondiabetic individuals with signs of retinopathy. However, there are two notable excep-

Table 1—Associations of retinal vascular changes with diabetes, hypertension, and cardiovascular diseases

Retinal vascular signs	Associations	Populations	References
Retinopathy	Impaired fasting glucose	ARIC	(67)
	Obesity	Hoorn	(23)
	Blood pressure	ARIC, AusDiab, BDES, BMES, CHS, Funagata, Hoorn, Rotterdam	(2,13–15,22–24,44)
	Incident hypertension	BDES	(57)
	Incident diabetes	ARIC, BDES	(56,57)
	Heart disease	BDES, CHS, ARIC	(14,59,114)
	Nephropathy	ARIC, CHS	(60,61)
	Cerebrovascular disease	ARIC, CHS, BDES	(14,33,34,114–117)
Retinal arteriolar narrowing	Blood pressure	Funagata, BDES, BMES, Rotterdam, ARIC, CHS	(10,22,24,32,37,87)
	Blood pressure in children	SCES, SCORM	(21)
	Measures of atherosclerosis	Rotterdam	(37)
	Waist-to-hip ratio	ARIC	(67)
	Incident hypertension	ARIC, BMES, BDES, Rotterdam	(58,88–90)
	Incident diabetes	ARIC, BDES	(64,65)
	Coronary heart disease	CHS	(98)
	Impaired fasting glucose	ARIC, MESA	(20,67)
Retinal venular dilatation	Measures of atherosclerosis	Rotterdam	(37)
	Obesity in children	SCORM	(69)
	Waist-to-hip ratio	ARIC	(67)
	Hypertriglyceridemia	ARIC	(67)
	Incident obesity	BMES	(118)
	Incident hypertension	BMES	(39)
	Incident impaired fasting glucose	Rotterdam	(66)
	Cerebrovascular diseases	Rotterdam, CHS	(96–98)
	Carotid artery disease	Rotterdam	(37)

AusDiab, Australian Diabetes, Obesity and Lifestyle Study; BDES, Beaver Dam Eye Study; BMES, Blue Mountain Eye Study; CHS, Cardiovascular Health Study; MESA, Multi-Ethnic Study of Atherosclerosis; SCES, Sydney Childhood Eye Study; SCORM, Singapore Cohort Study of Risk Factors for Myopia.

tions. First, in the Beaver Dam Study, among individuals aged <65 years at baseline, signs of retinopathy were associated with an increased 15-year incidence of diabetes (odds ratio [OR] 3.68 [95% CI 1.23–10.96]) (57). Second, in the ARIC Study, among participants with a family history of diabetes, signs of retinopathy were also associated with an increased 3-year risk of diabetes (2.3 [1.0–5.3]) (56). Thus, the literature suggests that isolated signs of retinopathy in individuals without diabetes are not necessarily markers of future diabetes risk, except possibly in younger individuals and in those with a family history of diabetes.

Similarly, there is conflicting evidence that isolated signs of retinopathy are markers of future hypertension risk. Data from the Beaver Dam Study showed that among nonhypertensive individuals, those with signs of retinopathy had a higher incidence of hypertension (OR 1.48 [95% CI 1.05–2.07]) (57), but these findings are not supported by other studies (15,45,58).

There is now substantial evidence

that isolated microaneurysms, hemorrhages, and cotton wool spots predict the development of clinical cardiovascular and cerebrovascular events independent of traditional risk factors (Table 1). Various population-based studies have shown associations of isolated signs of retinopathy with the risk of stroke (33), congestive heart failure (59), renal dysfunction (60,61), and measures of atherosclerosis (14,62,63). In the ARIC Study, the presence of retinopathy was associated with a threefold higher risk of congestive heart failure in those without previous coronary heart disease (relative risk 2.98 [95% CI 1.50–5.92]) (59). This later association suggests that microvascular disease may be important in the development of diabetic cardiomyopathy in the absence of established coronary artery disease.

RETINAL VASCULAR CALIBER

The associations and clinical significance of early retinal vascular caliber changes in individuals with diabetes and pre-diabetes, as well as hyperten-

sion and prehypertension, are summarized in Table 1.

Associations with diabetes and pre-diabetes

Consistent associations of retinal venular caliber with hyperglycemia, diabetes, and its complications are now emerging (20). Prospective data from three population-based cohorts have shown that changes in retinal vascular caliber may predict the development of type 2 diabetes (64,65) and impaired fasting glucose (66). In two early analyses, an association between smaller retinal AVR and incident diabetes was found in the ARIC Study (OR 1.71 [95% CI 1.13–2.57]; comparing smallest to largest AVR quintile) and the Beaver Dam Study (1.53 [1.03–2.27]; comparing smallest to largest AVR quartile) (64,65). Subsequently, the Rotterdam Study demonstrated that these associations reflected wider retinal venular caliber rather than narrower arteriolar caliber (1.23 [1.02–1.47]; per SD increase in venular caliber) (66). Reanalysis of the ARIC and Beaver Dam studies confirms this finding

(T.Y.W., unpublished data). Thus, it appears that wider retinal venular caliber is a marker of chronic hyperglycemia and the pre-diabetes state and reflects the early microvascular changes that occur in the development of diabetes.

Wider retinal venular caliber has also been linked to the metabolic syndrome and its components (20,37,67). In the Blue Mountains Study, wider retinal venular caliber was associated with the 5-year incidence of obesity among individuals of normal weight at baseline (OR 1.8 [95% CI 1.0–3.1]; comparing largest to lowest venular caliber quintile) (68). Similarly, in children aged 6–8 years, wider retinal venular caliber was also associated with higher BMI (69), suggesting that retinal venular caliber may be influenced by metabolic disorders early in life. There is also evidence that wider venular caliber is associated with various microvascular complications of diabetes, not only diabetic retinopathy (70,71) but also diabetic nephropathy (72).

Despite these observations, the pathophysiological processes underlying the association of wider retinal venular caliber with hyperglycemia, diabetes, and its complications are unclear. It has been speculated that retinal venular widening may be the result of increased blood flow associated with hyperglycemia (73) and retinal hypoxia (74). Alternatively, it may also reflect inflammatory processes implicated in the pathogenesis of impaired glucose metabolism (75), supported by epidemiological findings of wider retinal venules with elevated systemic inflammatory markers (17,20,37,76). Experiments have demonstrated that local inflammatory processes lead to wider retinal venular calibers. For example, administration of lipid hydroperoxide in the vitreous of rats leads to an increase in the retinal venular diameter (77). Similarly, administration of *Escherichia coli* endotoxin in human eyes has been reported to increase retinal venular diameter (78). Finally, retinal venular dilation may be related to endothelial dysfunction, reflecting an increased production of nitric oxide (79) secondary to higher levels of cytokines (80), seen often in association with impaired glucose metabolism (81,82) and diabetes (81).

Associations with hypertension and prehypertension

In distinct contrast to the association of hyperglycemia with retinal venular cali-

ber, there is now substantial evidence that hypertension preferentially affects retinal arteriolar caliber (83) (Table 1). It has long been known that generalized retinal arteriolar narrowing is an early characteristic sign of hypertensive retinopathy (8,84,85). More recent studies using quantitative measurements of retinal vascular caliber have now demonstrated a graded association of narrowed retinal arterioles with increasing blood pressure in different populations of various racial/ethnic groups and age-groups (10,20,22,24,32,37,86,87).

Of greater significance are prospective findings from four populations that show retinal arteriolar narrowing is a pre-clinical marker of hypertension risk. The ARIC Study (OR 1.62 [95% CI 1.21–2.18]; comparing smallest to largest AVR quintile) (58), the Beaver Dam Study (1.82 [1.39–2.40]; comparing smallest to largest AVR quartile) (88), the Blue Mountains Study (2.6 [1.7–3.9]; comparing smallest to largest arteriolar caliber quintile) (89), and the Rotterdam Study (1.38 [1.23–1.55]; per SD decrease in arteriolar caliber) (90) all reported that among individuals without hypertension at baseline, those with narrowed retinal arterioles had a higher risk of hypertension in the subsequent 3–10 years, independent of baseline blood pressure levels, BMI, and other known hypertension risk factors.

These observations support the hypothesis that peripheral vascular resistance, reflected by retinal arteriolar narrowing, is an important contributing factor for hypertension development (91). Added support to this hypothesis comes from a recent genome-wide linkage analysis from the Beaver Dam Study, which demonstrated that associations of retinal arteriolar diameter to multiple genetic loci are linked to regulation of blood pressure, endothelial function, and vasculogenesis (92). Thus, retinal arteriolar narrowing may be considered a surrogate marker of an individual's genetic predisposition to hypertension development (93).

Finally, a recent study has shown that the association between higher blood pressure and retinal arteriolar narrowing is detectable in healthy children aged 6–8 years (21), reinforcing the concept that the effects of higher childhood blood pressure may have an adverse effect on the microcirculation (94,95).

Associations with cardiovascular diseases

In addition to their associations with diabetes and hypertension, changes in retinal vascular caliber have also been linked to a range of cardiovascular diseases (Table 1). Wider retinal venular caliber has been associated with carotid artery disease (37), magnetic resonance imaging–detected lacunar infarcts and white matter lesions (96), and clinical stroke events (97,98). In the Cardiovascular Health Study, wider retinal venular caliber was predictive of incident coronary heart disease (rate ratio 3.0 [95% CI 1.6–5.7]; comparing largest to smallest venular caliber quartile) and incident stroke (2.2 [1.1–4.3]), whereas narrower arteriolar caliber was predictive of incident coronary heart disease (2.0 [1.1–3.7]; comparing smallest to largest arteriolar caliber quartile) (98). These findings suggest that both wider venular caliber and narrower arteriolar caliber may be markers of early subclinical cardiovascular disease.

CHANGES IN RETINAL VASCULAR ARCHITECTURE —

New imaging methods have allowed the measurement of other architectural changes in the retinal microvasculature. Hypertension, for example, has been associated with an increase in the retinal arteriolar length-to-diameter ratio (99,100), increased retinal venular tortuosity (99), reduced branching angle at arteriole bifurcations (101), and reduced microvascular density (99,101,102).

Some of these retinal changes have also been shown to be associated with increased cardiovascular risk. For example, the Beaver Dam Study demonstrated that suboptimal arteriolar bifurcation and decreased arteriolar tortuosity are associated with coronary heart mortality (103).

IMPLICATIONS FOR RESEARCH AND CLINICAL MANAGEMENT —

It is now well recognized that individuals with impaired glucose metabolism or pre-diabetes have higher mortality from cardiovascular disease (104–106). Similarly, individuals with high to normal blood pressure or prehypertension (107) are more likely to develop cardiovascular events (108,109). To permit appropriate preventative strategies, there is therefore great interest in early detection of individuals with pre-diabetes and prehypertension.

This review suggests that retinal image analysis offers a novel noninvasive

Downloaded from <http://ada.silverchair.com/care/article-pdf/30/10/2708/595553/zac01007002708.pdf> by guest on 17 April 2024

measurement of early changes in the vasculature—not detectable on routine clinical examination—that may allow the identification of individuals at risk of diabetes and hypertension and their subsequent complications. Retinal vascular imaging might also permit physicians to optimize management of individuals with established diabetes and/or hypertension. For example, retinal vascular imaging may allow monitoring of chronic variations in glucose and blood pressure, as well as the presence and severity of subclinical microvascular damage. However, a number of issues should be resolved before retinal vascular imaging can be utilized in clinical practice.

First, despite a large body of data on the associations and risk prediction of retinal vascular caliber measurement in different population-based studies, there is no accepted standardized classification of retinal vascular changes, and a lack of age-, sex-, body size-, and blood pressure-specific normative data. New studies of retinal vascular changes in children, who are generally free of many systemic conditions, may provide these reference data (21,110).

Second, for retinal vascular imaging to be useful for risk stratification, there must be a demonstration of independent predictive value that substantially adds to traditional methods. This has not been conclusively demonstrated. Different analytical methods have hampered the comparison of results between studies, and application-common methods in different studies will allow data pooling to generate more valid risk estimates. Additionally, the role of novel measures of retinal vascular structure (99,103,111–113) in predicting diseases remains to be determined.

Third, the predictive value of retinal vascular imaging is currently based on associations seen in large population-based samples (114–117). It is unclear whether the retinal measurements are sufficiently precise to differentiate risk at an individual level.

Finally, it is unknown whether modification of risk factors (e.g., increased physical activity, reduction in weight) or institution of treatment (e.g., diabetes and antihypertensive medications) may improve retinal vascular measures and whether this is associated with lowered risks of diabetes, hypertension, and their complications. This remains an important area of future research.

In conclusion, measurement of reti-

nal vascular changes using new imaging techniques offers great potential to advance our understanding of the early pathophysiological pathways of diabetes and hypertension development. Recent studies support the concept that the retinal vasculature provides a summary measure of lifetime exposure to various processes involved in the development of diabetes and hypertension. Furthermore, these studies suggest that the effects of glucose and blood pressure on the retinal microvasculature are graded and continuous, and our current definitions of diabetic and hypertensive retinopathy are arbitrary and do not capture early disease. Future research is clearly needed to assess the ability of retinal vascular imaging to provide clinically useful information that adds to existing risk prediction models of diabetes and hypertension.

References

- Ciulla TA, Amador AG, Zinman B: Diabetic retinopathy and diabetic macular edema: pathophysiology, screening, and novel therapies. *Diabetes Care* 26:2653–2664, 2003
- Tapp RJ, Shaw JE, Harper CA, de Courten MP, Balkau B, McCarty DJ, Taylor HR, Welborn TA, Zimmet PZ: The prevalence of and factors associated with diabetic retinopathy in the Australian population. *Diabetes Care* 26:1731–1737, 2003
- Klein R, Klein BE, Moss SE, Davis MD, DeMets DL: Glycosylated hemoglobin predicts the incidence and progression of diabetic retinopathy. *JAMA* 260:2864–2871, 1988
- The effect of intensive treatment of diabetes on the development and progression of long-term complications in insulin-dependent diabetes mellitus: the Diabetes Control and Complications Trial Research Group. *N Engl J Med* 329:977–986, 1993
- The UK Prospective Diabetes Study Group: Intensive blood-glucose control with sulphonylureas or insulin compared with conventional treatment and risk of complications in patients with type 2 diabetes (UKPDS 33). *Lancet* 352:837–853, 1998
- The UK Prospective Diabetes Study Group: Tight blood pressure control and risk of macrovascular and microvascular complications in type 2 diabetes: UKPDS 38. *BMJ* 317:703–713, 1998
- Keech A, Simes RJ, Barter P, Best J, Scott R, Taskinen MR, Forder P, Pillai A, Davis T, Glasziou P, Drury P, Kesaniemi YA, Sullivan D, Hunt D, Colman P, d'Emden M, Whiting M, Ehnholm C, Laakso M: Effects of long-term fenofibrate therapy on cardiovascular events in 9795 people with type 2 diabetes mellitus (the FIELD study): randomised controlled trial. *Lancet* 366:1849–1861, 2005
- Wong TY, Mitchell P: Hypertensive retinopathy. *N Engl J Med* 351:2310–2317, 2004
- Wong T, Mitchell P: The eye in hypertension. *Lancet* 369:425–435, 2007
- Leung H, Wang JJ, Rochtchina E, Tan AG, Wong TY, Klein R, Hubbard LD, Mitchell P: Relationships between age, blood pressure, and retinal vessel diameters in an older population. *Invest Ophthalmol Vis Sci* 44:2900–2904, 2003
- Sharp PS, Chaturvedi N, Wormald R, McKeigue PM, Marmot MG, Young SM: Hypertensive retinopathy in Afro-Caribbeans and Europeans: prevalence and risk factor relationships. *Hypertension* 25:1322–1325, 1995
- Wang JJ, Mitchell P, Leung H, Rochtchina E, Wong TY, Klein R: Hypertensive retinal vessel wall signs in a general older population: the Blue Mountains Eye Study. *Hypertension* 42:534–541, 2003
- Yu T, Mitchell P, Berry G, Li W, Wang JJ: Retinopathy in older persons without diabetes and its relationship to hypertension. *Arch Ophthalmol* 116:83–89, 1998
- Wong TY, Klein R, Sharrett AR, Manolio TA, Hubbard LD, Marino EK, Kuller L, Burke G, Tracy RP, Polak JF, Gottdiener JS, Siscovick DS: The prevalence and risk factors of retinal microvascular abnormalities in older persons: the Cardiovascular Health Study. *Ophthalmology* 110:658–666, 2003
- Klein R, Klein BE, Moss SE, Wang Q: Hypertension and retinopathy, arteriolar narrowing, and arteriovenous nicking in a population. *Arch Ophthalmol* 112:92–98, 1994
- Klein R, Klein BE, Moss SE: The relation of systemic hypertension to changes in the retinal vasculature: the Beaver Dam Eye Study. *Trans Am Ophthalmol Soc* 95:329–348, 1997
- Klein R, Sharrett AR, Klein BE, Chambless LE, Cooper LS, Hubbard LD, Evans G: Are retinal arteriolar abnormalities related to atherosclerosis? The Atherosclerosis Risk in Communities Study. *Arterioscler Thromb Vasc Biol* 20:1644–1650, 2000
- Sharrett AR, Hubbard LD, Cooper LS, Sorlie PD, Brothers RJ, Nieto FJ, Pinsky JL, Klein R: Retinal arteriolar diameters and elevated blood pressure: the Atherosclerosis Risk in Communities Study. *Am J Epidemiol* 150:263–270, 1999
- Duncan BB, Wong TY, Tyroler HA, Davis CE, Fuchs FD: Hypertensive retinopathy and incident coronary heart disease in high risk men. *Br J Ophthalmol* 86:1002–1006, 2002
- Wong TY, Islam FM, Klein R, Klein BE,

- Cotch MF, Castro C, Sharrett AR, Shahar E: Retinal vascular caliber, cardiovascular risk factors, and inflammation: the multi-ethnic study of atherosclerosis (MESA). *Invest Ophthalmol Vis Sci* 47:2341–2350, 2006
21. Mitchell P, Cheung N, de Haseth K, Taylor B, Rochtchina E, Islam FMA, Wang JJ, Saw SM, Wong TY: Blood pressure and retinal arteriolar narrowing in children. *Hypertension* 49:1156–1162, 2007
 22. Hubbard LD, Brothers RJ, King WN, Clegg LX, Klein R, Cooper LS, Sharrett AR, Davis MD, Cai J: Methods for evaluation of retinal microvascular abnormalities associated with hypertension/sclerosis in the Atherosclerosis Risk in Communities Study. *Ophthalmology* 106:2269–2280, 1999
 23. van Leiden HA, Dekker JM, Moll AC, Nijpels G, Heine RJ, Bouter LM, Stehouwer CD, Polak BC: Blood pressure, lipids, and obesity are associated with retinopathy: the Hoorn Study. *Diabetes Care* 25:1320–1325, 2002
 24. Kawasaki R, Wang JJ, Rochtchina E, Taylor B, Wong TY, Tominaga M, Kato T, Daimon M, Ozumi T, Kawata S, Kayama T, Yamashita H, Mitchell P: Cardiovascular risk factors and retinal microvascular signs in an adult Japanese population: the Funagata Study. *Ophthalmology* 113:1378–1384, 2006
 25. Couper DJ, Klein R, Hubbard LD, Wong TY, Sorlie PD, Cooper LS, Brothers RJ, Nieto FJ: Reliability of retinal photography in the assessment of retinal microvascular characteristics: the Atherosclerosis Risk in Communities Study. *Am J Ophthalmol* 133:78–88, 2002
 26. Sherry LM, Wang JJ, Rochtchina E, Wong T, Klein R, Hubbard L, Mitchell P: Reliability of computer-assisted retinal vessel measurement in a population. *Clin Experiment Ophthalmol* 30:179–182, 2002
 27. Li H, Hsu W, Lee ML, Wong TY: Automatic grading of retinal vessel caliber. *IEEE Trans Biomed Eng* 52:1352–1355, 2005
 28. Wong TY, Knudtson MD, Klein R, Klein BE, Meuer SM, Hubbard LD: Computer-assisted measurement of retinal vessel diameters in the Beaver Dam Eye Study: methodology, correlation between eyes, and effect of refractive errors. *Ophthalmology* 111:1183–1190, 2004
 29. Wagener HP, Clay GE, Gipner JF: Classification of retinal lesions in the presence of vascular hypertension: report submitted to the American Ophthalmological Society by the committee on Classification of Hypertensive Disease of the Retina. *Trans Am Ophthalmol Soc* 45:57–73, 1947
 30. Parr JC, Spears GF: General caliber of the retinal arteries expressed as the equivalent width of the central retinal artery. *Am J Ophthalmol* 77:472–477, 1974
 31. Parr JC, Spears GF: Mathematic relationships between the width of a retinal artery and the widths of its branches. *Am J Ophthalmol* 77:478–483, 1974
 32. Wong TY, Klein R, Klein BE, Meuer SM, Hubbard LD: Retinal vessel diameters and their associations with age and blood pressure. *Invest Ophthalmol Vis Sci* 44:4644–4650, 2003
 33. Wong TY, Klein R, Couper DJ, Cooper LS, Shahar E, Hubbard LD, Wofford MR, Sharrett AR: Retinal microvascular abnormalities and incident stroke: the Atherosclerosis Risk in Communities Study. *Lancet* 358:1134–1140, 2001
 34. Mitchell P, Wang JJ, Wong TY, Smith W, Klein R, Leeder SR: Retinal microvascular signs and risk of stroke and stroke mortality. *Neurology* 65:1005–1009, 2005
 35. Wong TY, Klein R, Sharrett AR, Duncan BB, Couper DJ, Tielsch JM, Klein BE, Hubbard LD: Retinal arteriolar narrowing and risk of coronary heart disease in men and women: the Atherosclerosis Risk in Communities Study. *JAMA* 287:1153–1159, 2002
 36. Patton N, Aslam T, Macgillivray T, Dhillion B, Constable I: Asymmetry of retinal arteriolar branch widths at junctions affects ability of formulae to predict trunk arteriolar widths. *Invest Ophthalmol Vis Sci* 47:1329–1333, 2006
 37. Ikram MK, de Jong FJ, Vingerling JR, Witteman JC, Hofman A, Breteler MM, de Jong PT: Are retinal arteriolar or venular diameters associated with markers for cardiovascular disorders? The Rotterdam Study. *Invest Ophthalmol Vis Sci* 45:2129–2134, 2004
 38. Liew G, Sharrett AR, Kronmal R, Klein R, Wong TY, Mitchell P, Kifley A, Wang JJ: Measurement of retinal vascular caliber: issues and alternatives to using the arteriole to venule ratio. *Invest Ophthalmol Vis Sci* 48:52–57, 2007
 39. Liew G, Wong TY, Mitchell P, Wang JJ: Are narrower or wider retinal venules associated with incident hypertension? *Hypertension* 48:e10, 2006
 40. Patton N, Aslam TM, MacGillivray T, Deary IJ, Dhillion B, Eikelboom RH, Yegesan K, Constable IJ: Retinal image analysis: concepts, applications and potential. *Prog Retin Eye Res* 25:99–127, 2006
 41. Leibowitz HM, Krueger DE, Maunder LR, Milton RC, Kini MM, Kahn HA, Nickerson RJ, Pool J, Colton TL, Ganley JP, Loewenstein JJ, Dawber TR: The Framingham Eye Study monograph: an ophthalmological and epidemiological study of cataract, glaucoma, diabetic retinopathy, macular degeneration, and visual acuity in a general population of 2631 adults, 1973–1975. *Surv Ophthalmol* 24:335–610, 1980
 42. Svarsdudd K, Wedel H, Aurell E, Tibblin G: Hypertensive eye ground changes: prevalence, relation to blood pressure and prognostic importance: the study of men born in 1913. *Acta Med Scand* 204:159–167, 1978
 43. McDonough JR, Garrison GE, Hames CG: Blood pressure and hypertensive disease among negroes and whites: a study in Evans County, Georgia. *Ann Intern Med* 61:208–228, 1964
 44. Stolk RP, Vingerling JR, de Jong PT, Dielemans I, Hofman A, Lamberts SW, Pols HA, Grobbee DE: Retinopathy, glucose, and insulin in an elderly population: the Rotterdam Study. *Diabetes* 44:11–15, 1995
 45. Cugati S, Cikamatana L, Wang JJ, Kifley A, Liew G, Mitchell P: Five-year incidence and progression of vascular retinopathy in persons without diabetes: the Blue Mountains Eye Study. *Eye* 20:1239–1245, 2006
 46. Wong TY, Barr EL, Tapp RJ, Harper CA, Taylor HR, Zimmet PZ, Shaw JE: Retinopathy in persons with impaired glucose metabolism: the Australian Diabetes Obesity and Lifestyle (AusDiab) study. *Am J Ophthalmol* 140:1157–1159, 2005
 47. The prevalence of retinopathy in impaired glucose tolerance and recent-onset diabetes in the Diabetes Prevention Program. *Diabet Med* 24:137–144, 2007
 48. Wong TY, Klein R, Islam FM, Cotch MF, Couper DJ, Klein BE, Hubbard L, Sharrett AR: Three-year incidence and cumulative prevalence of retinopathy: the Atherosclerosis Risk in Communities Study. *Am J Ophthalmol* 143:970–976, 2007
 49. Wong TY, Klein R, Duncan BB, Nieto FJ, Klein BE, Couper DJ, Hubbard LD, Sharrett AR: Racial differences in the prevalence of hypertensive retinopathy. *Hypertension* 41:1086–1091, 2003
 50. van Hecke MV, Dekker JM, Nijpels G, Moll AC, Heine RJ, Bouter LM, Polak BC, Stehouwer CD: Inflammation and endothelial dysfunction are associated with retinopathy: the Hoorn Study. *Diabetologia* 48:1300–1306, 2005
 51. Miyamoto K, Khosrof S, Bursell SE, Rohan R, Murata T, Clermont AC, Aiello LP, Ogura Y, Adam AP: Prevention of leukostasis and vascular leakage in streptozotocin-induced diabetic retinopathy via intercellular adhesion molecule-1 inhibition. *Proc Natl Acad Sci U S A* 96:10836–10841, 1999
 52. Izuora KE, Chase HP, Jackson WE, Coll JR, Osberg IM, Gottlieb PA, Rewers MJ, Garg SK: Inflammatory markers and diabetic retinopathy in type 1 diabetes. *Diabetes Care* 28:714–715, 2005
 53. Joussen AM, Poulaki V, Le ML, Koizumi K, Esser C, Janicki H, Schraermeyer U, Kociok N, Fauser S, Kirchhof B, Kern TS,

Downloaded from <http://ada.lww.com/ce/article-pdf/30/10/2708/595553/zdc0100702708.pdf> by guest on 17 April 2024

- Adamis AP: A central role for inflammation in the pathogenesis of diabetic retinopathy. *FASEB J* 18:1450–1452, 2004
54. Harris MI, Klein R, Welborn TA, Knudman MW: Onset of NIDDM occurs at least 4–7 yr before clinical diagnosis. *Diabetes Care* 15:815–819, 1992
 55. Cugati S, Mitchell P, Wang JJ: Do retinopathy signs in non-diabetic individuals predict the subsequent risk of diabetes? *Br J Ophthalmol* 90:928–929, 2006
 56. Wong TY, Mohamed Q, Klein R, Couper DJ: Do retinopathy signs in non-diabetic individuals predict the subsequent risk of diabetes? *Br J Ophthalmol* 90:301–303, 2006
 57. Klein R, Klein BEK, Mos SE, Wong TY: The relationship of retinopathy in persons without diabetes to the 15-year incidence of diabetes and hypertension: Beaver Dam Eye Study. *Trans Am Ophthalmol Soc* 104:98–107, 2006
 58. Wong TY, Klein R, Sharrett AR, Duncan BB, Couper DJ, Klein BE, Hubbard LD, Nieto FJ: Retinal arteriolar diameter and risk for hypertension. *Ann Intern Med* 140:248–255, 2004
 59. Wong TY, Rosamond W, Chang PP, Couper DJ, Sharrett AR, Hubbard LD, Folsom AR, Klein R: Retinopathy and risk of congestive heart failure. *JAMA* 293:63–69, 2005
 60. Wong TY, Coresh J, Klein R, Muntner P, Couper DJ, Sharrett AR, Klein BE, Heiss G, Hubbard LD, Duncan BB: Retinal microvascular abnormalities and renal dysfunction: the atherosclerosis risk in communities study. *J Am Soc Nephrol* 15:2469–2476, 2004
 61. Edwards MS, Wilson DB, Craven TE, Stafford J, Fried LF, Wong TY, Klein R, Burke GL, Hansen KJ: Associations between retinal microvascular abnormalities and declining renal function in the elderly population: the Cardiovascular Health Study. *Am J Kidney Dis* 46:214–224, 2005
 62. Rema M, Mohan V, Deepa R, Ravikumar R: Association of carotid intima-media thickness and arterial stiffness with diabetic retinopathy: the Chennai Urban Rural Epidemiology Study (CURES-2). *Diabetes Care* 27:1962–1967, 2004
 63. Wong TY, Klein R, Islam FM, Cotch MF, Folsom AR, Klein BE, Sharrett AR, Shea S: Diabetic retinopathy in a multi-ethnic cohort in the United States. *Am J Ophthalmol* 141:446–455, 2006
 64. Wong TY, Klein R, Sharrett AR, Schmidt MI, Pankow JS, Couper DJ, Klein BE, Hubbard LD, Duncan BB: Retinal arteriolar narrowing and risk of diabetes mellitus in middle-aged persons. *JAMA* 287:2528–2533, 2002
 65. Wong TY, Shankar A, Klein R, Klein BE, Hubbard LD: Retinal arteriolar narrowing, hypertension, and subsequent risk of diabetes mellitus. *Arch Intern Med* 165:1060–1065, 2005
 66. Ikram MK, Janssen JA, Roos AM, Rietveld I, Witteman JC, Breteler MM, Hofman A, van Duijn CM, de Jong PT: Retinal vessel diameters and risk of impaired fasting glucose or diabetes: the Rotterdam Study. *Diabetes* 55:506–510, 2006
 67. Wong TY, Duncan BB, Golden SH, Klein R, Couper DJ, Klein BE, Hubbard LD, Sharrett AR, Schmidt MI: Associations between the metabolic syndrome and retinal microvascular signs: the Atherosclerosis Risk In Communities study. *Invest Ophthalmol Vis Sci* 45:2949–2954, 2004
 68. Wang JJ, Taylor B, Wong TY, Chua B, Rochtchina E, Klein R, Mitchell P: Retinal vessel diameters and obesity: a population-based study in older persons. *Obesity (Silver Spring)* 14:206–214, 2006
 69. Cheung N, Saw SM, Islam FM, Rogers SL, Shankar A, de Haseth K, Mitchell P, Wong TY: BMI and retinal vascular caliber in children. *Obesity (Silver Spring)* 15:209–215, 2007
 70. Klein R, Klein BE, Moss SE, Wong TY, Sharrett AR: Retinal vascular caliber in persons with type 2 diabetes: the Wisconsin Epidemiological Study of Diabetic Retinopathy: XX. *Ophthalmology* 113:1488–1498, 2006
 71. Klein R, Klein BE, Moss SE, Wong TY, Hubbard L, Cruickshanks KJ, Palta M: Retinal vascular abnormalities in persons with type 1 diabetes: the Wisconsin Epidemiologic Study of Diabetic Retinopathy: XVIII. *Ophthalmology* 110:2118–2125, 2003
 72. Wong TY, Shankar A, Klein R, Klein BE: Retinal vessel diameters and the incidence of gross proteinuria and renal insufficiency in people with type 1 diabetes. *Diabetes* 53:179–184, 2004
 73. Grunwald JE, Riva CE, Baine J, Brucker AJ: Total retinal volumetric blood flow rate in diabetic patients with poor glycemic control. *Invest Ophthalmol Vis Sci* 33:356–363, 1992
 74. Saldivar E, Cabrales P, Tsai AG, Intaglietta M: Microcirculatory changes during chronic adaptation to hypoxia. *Am J Physiol Heart Circ Physiol* 285:H2064–H2071, 2003
 75. Caballero AE: Metabolic and vascular abnormalities in subjects at risk for type 2 diabetes: the early start of a dangerous situation. *Arch Med Res* 36:241–249, 2005
 76. Klein R, Klein BE, Knudtson MD, Wong TY, Tsai MY: Are inflammatory factors related to retinal vessel caliber? The Beaver Dam Eye Study. *Arch Ophthalmol* 124:87–94, 2006
 77. Tamai K, Matsubara A, Tomida K, Matsuda Y, Morita H, Armstrong D, Ogura Y: Lipid hydroperoxide stimulates leukocyte-endothelium interaction in the retinal microcirculation. *Exp Eye Res* 75:69–75, 2002
 78. Kolodjaschna J, Berisha F, Lung S, Schaller G, Polska E, Jilma B, Wolzt M, Schmetterer L: LPS-induced microvascular leukocytosis can be assessed by blue-field entoptic phenomenon. *Am J Physiol Heart Circ Physiol* 287:H691–H694, 2004
 79. Wilkinson-Berka JL: Vasoactive factors and diabetic retinopathy: vascular endothelial growth factor, cyclooxygenase-2 and nitric oxide. *Curr Pharm Des* 10:3331–3348, 2004
 80. Chester AH, Borland JA, Buttery LD, Mitchell JA, Cunningham DA, Hafizi S, Hoare GS, Springall DR, Polak JM, Yacoub MH: Induction of nitric oxide synthase in human vascular smooth muscle: interactions between proinflammatory cytokines. *Cardiovasc Res* 38:814–821, 1998
 81. de Rekeneire N, Peila R, Ding J, Colbert LH, Visser M, Shorr RI, Kritchevsky SB, Kuller LH, Strotmeyer ES, Schwartz AV, Vellas B, Harris TB: Diabetes, hyperglycemia, and inflammation in older individuals: the health, aging and body composition study. *Diabetes Care* 29:1902–1908, 2006
 82. Ling PR, Mueller C, Smith RJ, Bistrrian BR: Hyperglycemia induced by glucose infusion causes hepatic oxidative stress and systemic inflammation, but not STAT3 or MAP kinase activation in liver in rats. *Metabolism* 52:868–874, 2003
 83. Nguyen TT, Wong TY: Retinal vascular manifestations of metabolic disorders. *Trends Endocrinol Metab* 17:262–268, 2006
 84. Tso MO, Jampol LM: Pathophysiology of hypertensive retinopathy. *Ophthalmology* 89:1132–1145, 1982
 85. Walsh JB: Hypertensive retinopathy: description, classification, and prognosis. *Ophthalmology* 89:1127–1131, 1982
 86. Leung H, Wang JJ, Rochtchina E, Wong TY, Klein R, Mitchell P: Impact of current and past blood pressure on retinal arteriolar diameter in an older population. *J Hypertens* 22:1543–1549, 2004
 87. Wong TY, Hubbard LD, Klein R, Marino EK, Kronmal R, Sharrett AR, Siscovick DS, Burke G, Tielsch JM: Retinal microvascular abnormalities and blood pressure in older people: the Cardiovascular Health Study. *Br J Ophthalmol* 86:1007–1013, 2002
 88. Wong TY, Shankar A, Klein R, Klein BE, Hubbard LD: Prospective cohort study of retinal vessel diameters and risk of hypertension. *BMJ* 329:79, 2004
 89. Smith W, Wang JJ, Wong TY, Rochtchina E, Klein R, Leeder SR, Mitchell P: Retinal arteriolar narrowing is associated with 5-year incident severe hypertension.

- sion: the Blue Mountains Eye Study. *Hypertension* 44:442–447, 2004
90. Ikram MK, Witteman JC, Vingerling JR, Breteler MM, Hofman A, de Jong PT: Retinal vessel diameters and risk of hypertension: the Rotterdam Study. *Hypertension* 47:189–194, 2006
 91. Mulvany MJ: Are vascular abnormalities a primary cause or secondary consequence of hypertension? *Hypertension* 18:152–157, 1991
 92. Xing C, Klein BE, Klein R, Jun G, Lee KE, Iyengar SK: Genome-wide linkage study of retinal vessel diameters in the Beaver Dam Eye Study. *Hypertension* 47:797–802, 2006
 93. Wang JJ, Wong TY: Genetic determinants of retinal vascular caliber: additional insights into hypertension pathogenesis. *Hypertension* 47:644–645, 2006
 94. Ingelfinger JR: Pediatric antecedents of adult cardiovascular disease—awareness and intervention. *N Engl J Med* 350:2123–2126, 2004
 95. Barker DJ, Osmond C, Golding J, Kuh D, Wadsworth ME: Growth in utero, blood pressure in childhood and adult life, and mortality from cardiovascular disease. *BMJ* 298:564–567, 1989
 96. Ikram MK, De Jong FJ, Van Dijk EJ, Prins ND, Hofman A, Breteler MM, De Jong PT: Retinal vessel diameters and cerebral small vessel disease: the Rotterdam Scan Study. *Brain* 129:182–188, 2006
 97. Ikram MK, de Jong FJ, Bos MJ, Vingerling JR, Hofman A, Koudstaal PJ, de Jong PT, Breteler MM: Retinal vessel diameters and risk of stroke: the Rotterdam Study. *Neurology* 66:1339–1343, 2006
 98. Wong TY, Kamineni A, Klein R, Sharrett AR, Klein BE, Siscovick DS, Cushman M, Duncan BB: Quantitative retinal venular caliber and risk of cardiovascular disease in older persons: the cardiovascular health study. *Arch Intern Med* 166:2388–2394, 2006
 99. Hughes AD, Martinez-Perez E, Jabbar AS, Hassan A, Witt NW, Mistry PD, Chapman N, Stanton AV, Beevers G, Pedrinelli R, Parker KH, Thom SA: Quantification of topological changes in retinal vascular architecture in essential and malignant hypertension. *J Hypertens* 24:889–894, 2006
 100. King LA, Stanton AV, Sever PS, Thom SA, Hughes AD: Arteriolar length-diameter (L:D) ratio: a geometric parameter of the retinal vasculature diagnostic of hypertension. *J Hum Hypertens* 10:417–418, 1996
 101. Stanton AV, Wasan B, Cerutti A, Ford S, Marsh R, Sever PP, Thom SA, Hughes AD: Vascular network changes in the retina with age and hypertension. *J Hypertens* 13:1724–1728, 1995
 102. Kutschbach P, Wolf S, Sieveking M, Ittel TH, Schulte K, Reim M: Retinal capillary density in patients with arterial hypertension: 2-year follow-up. *Graefes Arch Clin Exp Ophthalmol* 236:410–414, 1998
 103. Witt N, Wong TY, Hughes AD, Chaturvedi N, Klein BE, Evans R, McNamara M, Thom SA, Klein R: Abnormalities of retinal microvascular structure and risk of mortality from ischemic heart disease and stroke. *Hypertension* 47:975–981, 2006
 104. Sorkin JD, Muller DC, Fleg JL, Andres R: The relation of fasting and 2-h postchallenge plasma glucose concentrations to mortality: data from the Baltimore Longitudinal Study of Aging with a critical review of the literature. *Diabetes Care* 28:2626–2632, 2005
 105. Brunner EJ, Shipley MJ, Witte DR, Fuller JH, Marmot MG: Relation between blood glucose and coronary mortality over 33 years in the Whitehall Study. *Diabetes Care* 29:26–31, 2006
 106. Glucose tolerance and mortality: comparison of WHO and American Diabetes Association diagnostic criteria: the DECODE study group: European Diabetes Epidemiology Group: Diabetes Epidemiology: Collaborative analysis Of Diagnostic criteria in Europe. *Lancet* 354:617–621, 1999
 107. Gu D, Wildman RP, Wu X, Reynolds K, Huang J, Chen CS, He J: Incidence and predictors of hypertension over 8 years among Chinese men and women. *J Hypertens* 25:517–523, 2007
 108. Chobanian AV, Bakris GL, Black HR, Cushman WC, Green LA, Izzo JL Jr, Jones DW, Materson BJ, Oparil S, Wright JT Jr, Roccella EJ: The Seventh Report of the Joint National Committee on Prevention, Detection, Evaluation, and Treatment of High Blood Pressure: the JNC 7 report. *JAMA* 289:2560–2572, 2003
 109. Hsia J, Margolis KL, Eaton CB, Wenger NK, Allison M, Wu L, LaCroix AZ, Black HR: Prehypertension and cardiovascular disease risk in the Women's Health Initiative. *Circulation* 115:855–860, 2007
 110. Cheung N, Islam FM, Saw SM, Shankar A, de Haseth K, Mitchell P, Wong TY: Distribution and associations of retinal vascular caliber with ethnicity, gender, and birth parameters in young children. *Invest Ophthalmol Vis Sci* 48:1018–1024, 2007
 111. Gould DB, Phalan FC, van Mil SE, Sundberg JP, Vahedi K, Massin P, Bousser MG, Heutink P, Miner JH, Tournier-Lasserre E, John SW: Role of COL4A1 in small-vessel disease and hemorrhagic stroke. *N Engl J Med* 354:1489–1496, 2006
 112. Gekeler F, Shinoda K, Junger M, Bartz-Schmidt KU, Gelissen F: Familial retinal arterial tortuosity associated with tortuosity in nail bed capillaries. *Arch Ophthalmol* 124:1492–1494, 2006
 113. Muiesan ML, Grassi G: Assessment of retinal vascular changes in hypertension: new perspectives. *J Hypertens* 24:813–814, 2006
 114. Wong TY, Klein R, Nieto FJ, Klein BE, Sharrett AR, Meuer SM, Hubbard LD, Tielsch JM: Retinal microvascular abnormalities and 10-year cardiovascular mortality: a population-based case-control study. *Ophthalmology* 110:933–940, 2003
 115. Wong TY, Klein R, Sharrett AR, Couper DJ, Klein BE, Liao DP, Hubbard LD, Mosley TH: Cerebral white matter lesions, retinopathy, and incident clinical stroke. *JAMA* 288:67–74, 2002
 116. Wong TY, Mosley TH Jr, Klein R, Klein BE, Sharrett AR, Couper DJ, Hubbard LD: Retinal microvascular changes and MRI signs of cerebral atrophy in healthy, middle-aged people. *Neurology* 61:806–811, 2003
 117. Wong TY, Klein R, Sharrett AR, Nieto FJ, Boland LL, Couper DJ, Mosley TH, Klein BE, Hubbard LD, Szklo M: Retinal microvascular abnormalities and cognitive impairment in middle-aged persons: the Atherosclerosis Risk in Communities Study. *Stroke* 33:1487–1492, 2002