

# Acute Neuropathic Joint Disease

## A medical emergency?

AI LYN TAN, MRCP<sup>1,2</sup>  
ADAM GREENSTEIN, MRCP<sup>3</sup>

STEPHEN J. JARRETT, MRCP<sup>4</sup>  
DENNIS MCGONAGLE, PHD, FRCPI<sup>1,2</sup>

**C**harcot neuroarthropathy, or, as it is also known, neuropathic joint disease (NJD), is a particularly severe form of osteoarthritis. It is recognized by severe joint damage in the context of relatively little pain in the presence of neuropathy and associated with characteristic radiographic changes in well-established disease. Patients with diabetes are at particular risk of NJD; permanent disability through foot deformity or amputation as a consequence of peripheral neuropathy (1) and diabetes is now the leading cause of NJD. The midfoot or ankle joints are most commonly affected in diabetic patients (2). The limited epidemiologic data on NJD suggest that ~0.1–0.4% of patients with diabetes develop NJD (3), usually 10–15 years after the onset of diabetes, and up to 16% of diabetic patients with peripheral neuropathy have been reported to be affected by NJD (4), which therefore represents a considerable cause of diabetic ankle- and foot-related morbidity.

### Rapid progression of NJD

NJD often presents acutely, resulting in misdiagnosis and inappropriate treatment and consequently leading to disastrous damage and possible loss of the affected limb (3). Typically, in the acute phase, NJD presents as a warm, edematous, and erythematous joint (5,6). As a result of sensory neuropathy, there may be little pain or tenderness, and the patient may not even seek medical assistance. During examination, a bounding pedal pulse compared with the other limb is found (7). The radiographic changes of

chronic NJD include florid new bone formation, joint space loss, and severe joint destruction and deformity, but these characteristic changes are usually absent in early NJD. In this clinical context, cellulitis, osteomyelitis, or infection may be diagnosed instead and treated accordingly, and the window of opportunity for the initiation of treatment designed to minimize subsequent NJD joint deformity is lost.

We have previously reported a small series of acute NJD that initially showed normal ankle and foot radiographs but rapidly progressed, subsequently developing the characteristic osteoarthritic change with severe loss of function in the following months (8). At clinical presentation, the most characteristic changes on magnetic resonance imaging (MRI) were prominent bone edema with associated gadolinium enhancement suggestive of severe bone-based pathology. In one of these cases, a small subchondral fracture was identified on MRI, supporting the concept of bone microtraumatic damage as an initiating event. Contrast enhancement within the bones and the rapid bony destruction strongly suggest that at a cellular level, there is a large degree of bone osteoclastic activation in the early stages of disease. Our findings in early disease therefore support the neurotraumatic theory for NJD (9) but emphasize the importance of disease of the bone.

Acute NJD is still not well recognized by those involved in patient care, especially nonspecialists, to whom at-risk patients may present acutely. Also, the MRI appearances are not diagnostic and, for

example, could be seen in bone-stressing phenomenon, acute osteomyelitis, reflex sympathetic dystrophy, or, indeed, sepsis (10). Therefore, a strong degree of clinical suspicion is needed to facilitate reaching the correct diagnosis promptly. Figure 1 illustrates another recent example of a diabetic patient who presented with acute ankle and foot swelling, tenderness, and neuropathy. An MRI performed at clinical presentation showed florid bone and soft tissue edema with contrast enhancement within both. The plain radiograph at presentation was nondiagnostic, but within 3 months, the patient rapidly developed progressive joint damage and severe functional impairment.

### Bisphosphonates in NJD

Independent of MRI observations in the acute setting, studies utilizing bisphosphonates have shown good efficacy for the treatment of acute NJD (11–13). In these studies, patients treated with intravenous pamidronate were found to have significantly reduced skin temperature, reduction in bone-specific alkaline phosphatase and urinary deoxypyridinoline, and reduced bone turnover (12,13). It may be no coincidence that MRI in early NJD shows a prominent bone-based disease and that bisphosphonates are efficacious in established disease, since the principal site of action of these drugs is in the bone. The florid gadolinium enhancement on MRI suggests an active osteitic process, including osteoclastic activation, therefore providing one possible explanation for the observed efficacy of bisphosphonates. Bisphosphonates not only target osteoclasts but may also have direct anti-inflammatory properties that could be therapeutically advantageous at sites of disease. A recent study in established osteoarthritis has lent further support to the idea that bisphosphonates exert a beneficial effect on the joints via an action in the subchondral bone in osteoarthritis (14).

### NJD: a medical emergency

A medical condition becomes a medical emergency when there is a therapy available that can transform its natural history. Given these findings, it seems logical that prompt initiation of intravenous bisphos-

From the <sup>1</sup>Academic Unit of Musculoskeletal Disease, Chapel Allerton Hospital, Leeds, U.K.; the <sup>2</sup>Department of Rheumatology, Calderdale Royal Hospital, Halifax, U.K.; the <sup>3</sup>Department of Medicine for the Elderly, York Hospital, York, U.K.; and the <sup>4</sup>Department of Rheumatology, Pinderfields General Hospital, Wakefield, U.K.

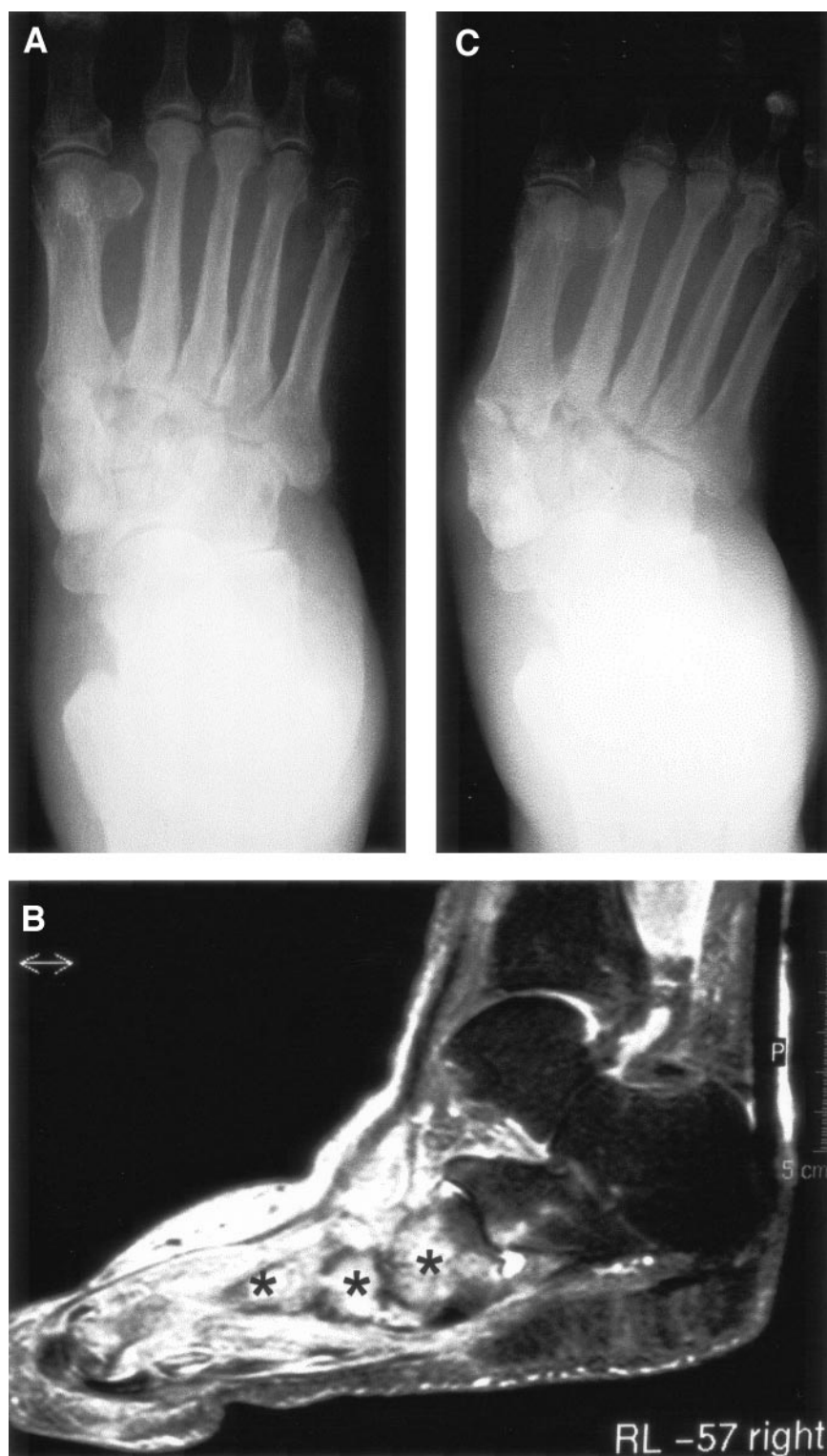
Address correspondence and reprint requests to Prof. Dennis McGonagle, Academic Unit of Musculoskeletal Disease, 2nd Floor, Chapel Allerton Hospital, Chapeltown Road, Leeds LS7 4SA, U.K. E-mail: d.g.mcgonagle@leeds.ac.uk.

Received for publication 29 July 2005 and accepted in revised form 21 August 2005.

**Abbreviations:** MRI, magnetic resonance imaging; NJD, neuropathic joint disease.

A table elsewhere in this issue shows conventional and Système International (SI) units and conversion factors for many substances.

© 2005 by the American Diabetes Association.



**Figure 1**—Imaging in a 67-year-old patient with a 10-year history of type 2 diabetes. The patient presented with a warm tender midfoot region that mimicked sepsis but without systemic signs of infection. A: Radiograph at disease presentation showing no obvious abnormalities in the midfoot region. B: Fat suppression MRI performed within a month of the radiograph showed florid bone edema with contrast enhancement in the midfoot region (asterisks) in addition to florid soft tissue edema. C: Within 3 months of presentation, the patient developed the typical clinical and radiographic changes of chronic NJD with foot deformity (lateral deviation of the metatarsophalangeal joints) and florid osteoarthritic changes with loss of joint space.

phonate therapy, ideally at clinical presentation, could have significant benefits for patients. The delay of therapy until radiographic damage develops, if it is not already present, will limit the benefits of therapy. It is possible that the benefits of bisphosphonates in clinical trials would be even greater if the drugs were used before irreversible joint damage sets in.

The optimal bisphosphonate dosing regimen, and indeed which bisphosphonate to use for acute NJD, remains to be defined. Thus far, there is evidence only for intravenous therapy, which seems logical given the likelihood of a quicker onset of action. With respect to dose and duration of intravenous therapy, a single dose of 90 mg pamidronate was associated with improvement in symptoms and signs and decreased bone turnover, as measured by urinary deoxypyridinoline, for up to 6 months (12). Based on these observations, the authors suggested that repeated dosing could be more effective. Whether oral maintenance therapy could be used following induction therapy is still a matter for debate. The role of alternative, longer-acting intravenous bisphosphonates, including ibandronate or zoledronic acid, remains to be assessed.

Presently, we would recommend the administration of a bisphosphonate such as intravenous pamidronate in a patient with diabetes and an acutely warm foot, as such therapy will be unlikely to have a deleterious effect in the case of osteomyelitis. We use a regimen designed for Paget's disease of the bone, which is comprised of a test dose of 30 mg pamidronate i.v. followed by five infusions of 60 mg at 2-week intervals (up to six infusions over 3 months), on the basis that this will be toxic to osteoclasts. Offloading, an essential therapeutic measure to prevent further neuropathic damage (15), is probably even more important in this context, as these patients may attempt to continue to walk after receiving bisphosphonate therapy, thereby causing further damage. This suggests that the earlier intravenous bisphosphonate therapy together with offloading is commenced, the greater the potential to prevent the rapid deterioration associated with this type of neuropathy.

## Conclusions

To date, imaging and therapeutic findings support the concept that therapies aimed at osteoclast modulation in general may have a significant future role in the therapy of NJD. The discovery of RANK-L (re-

ceptor activator of nuclear factor  $\kappa$ B ligand), which binds the RANK receptor on osteoclasts, leading to cell proliferation and differentiation (16), and OPG (osteoprotegerin), the physiological inhibitor of the RANK-L/RANK interaction, may provide novel targets for therapy. Indeed, this was elegantly reviewed recently by Jeffcoate (17). In addition, several other compounds currently under investigation as inhibitors of  $\alpha_v\beta_3$  integrin, which mediates adhesion of osteoclasts to bone surface, may have a role in this setting (18,19).

In summary, the recognition of acute NJD at clinical presentation is imperative and now possible. A high degree of suspicion by the clinician is essential since the MRI changes are not specific. Prompt and aggressive intravenous bisphosphonate therapy in conjunction with more traditional measures, such as offloading, may minimize joint damage and lead to better preservation of joint function. This also has implications for therapy development for NJD. Taken together, these changes could radically transform the diagnosis and management of acute NJD and elevate this condition to the status of endocrinological and rheumatological emergency.

## References

1. Sinacore DR: Acute Charcot arthropathy in patients with diabetes mellitus: healing times by foot location. *J Diabetes Complications* 12:287–293, 1998
2. Jeffcoate W, Lima J, Nobrega L: The Charcot foot. *Diabet Med* 17:253–258, 2000
3. Rajbhandari SM, Jenkins RC, Davies C, Tesfaye S: Charcot neuroarthropathy in diabetes mellitus. *Diabetologia* 45:1085–1096, 2002
4. Cavanagh PR, Young MJ, Adams JE, Vickers KL, Boulton AJ: Radiographic abnormalities in the feet of patients with diabetic neuropathy. *Diabetes Care* 17: 201–209, 1994
5. Allman RM, Brower AC, Kotlyarov EB: Neuropathic bone and joint disease. *Radiol Clin North Am* 26:1373–1381, 1988
6. Reiner M, Scurran BL, Karlin JM, Silvani SH: The neuropathic joint in diabetes mellitus. *Clin Podiatr Med Surg* 5:421–437, 1988
7. Wilson M: Charcot foot osteoarthropathy in diabetes mellitus. *Mil Med* 156:563–569, 1991
8. Greenstein AS, Marzo-Ortega H, Emery P, O'Connor P, McGonagle D: Magnetic resonance imaging as a predictor of progressive joint destruction in neuropathic joint disease. *Arthritis Rheum* 46:2814–2815, 2002
9. Gupta R: A short history of neuropathic arthropathy. *Clin Orthop Relat Res* 43–49, 1993
10. Weishaupt D, Schweitzer ME, Alam F, Karasick D, Wapner K: MR imaging of inflammatory joint diseases of the foot and ankle. *Skeletal Radiol* 28:663–669, 1999
11. Selby PL, Young MJ, Boulton AJ: Bisphosphonates: a new treatment for diabetic Charcot neuroarthropathy? *Diabet Med* 11:28–31, 1994
12. Jude EB, Selby PL, Burgess J, Lilleystone P, Mawer EB, Page SR, Donohoe M, Foster AV, Edmonds ME, Boulton AJ: Bisphosphonates in the treatment of Charcot neuroarthropathy: a double-blind randomised controlled trial. *Diabetologia* 44:2032–2037, 2001
13. Anderson JJ, Woelffer KE, Holtzman JJ, Jacobs AM: Bisphosphonates for the treatment of Charcot neuroarthropathy. *J Foot Ankle Surg* 43:285–289, 2004
14. Carbone LD, Nevitt MC, Wildy K, Barrow KD, Harris F, Felson D, Peterfy C, Visser M, Harris TB, Wang BW, Kritchevsky SB: The relationship of antiresorptive drug use to structural findings and symptoms of knee osteoarthritis. *Arthritis Rheum* 50: 3516–3525, 2004
15. Boulton AJ: Pressure and the diabetic foot: clinical science and offloading techniques. *Am J Surg* 187:17S–24S, 2004
16. Bell NH: RANK ligand and the regulation of skeletal remodeling. *J Clin Invest* 111: 1120–1122, 2003
17. Jeffcoate W: Vascular calcification and osteolysis in diabetic neuropathy—is RANK-L the missing link? *Diabetologia* 47:1488–1492, 2004
18. Rodan GA, Martin TJ: Therapeutic approaches to bone diseases. *Science* 289: 1508–1514, 2000
19. Duong LT, Rodan GA: Regulation of osteoclast formation and function. *Rev Endocr Metab Disord* 2:95–104, 2001