

Atrophy of Foot Muscles

A measure of diabetic neuropathy

HENNING ANDERSEN, MD, PHD¹

MICHAELA D. GJERSTAD, MD¹

JOHANNES JAKOBSEN, MD, PHD¹

OBJECTIVE — Diabetic neuropathy is a length-dependent process that leads to reduced muscle strength and atrophy of leg muscles in some patients. We hypothesized that intrinsic foot muscles are atrophied in diabetic neuropathy and that the degree of atrophy is a measure of motor dysfunction closely related to the neuropathic process.

RESEARCH DESIGN AND METHODS — Consecutive cross-sectional magnetic resonance images of the nondominant foot were obtained for stereological determination of the total volume of the intrinsic foot muscles (VFM) in 23 long-term diabetic patients with ($n = 15$) and without ($n = 8$) chronic neuropathy and in 23 matched healthy nondiabetic control subjects. Based on clinical examination, nerve conduction studies, and quantitative sensory examination, a neuropathy rank-sum score was calculated for each patient.

RESULTS — Total VFM was 86 ± 52 , 165 ± 34 , and 168 ± 42 cm³ in neuropathic patients, nonneuropathic patients, and healthy control subjects, respectively ($P < 0.001$). There was a close inverse relationship between the neuropathy rank-sum score and the VFM ($r = -0.75$, $P < 1 \times 10^{-5}$).

CONCLUSIONS — Total volume of the foot muscles is halved in patients with diabetic neuropathy. Atrophy of foot muscles is closely related to the severity of neuropathy and reflects motor dysfunction.

Diabetes Care 27:2382–2385, 2004

Loss of ankle jerks and of sensation in the feet are early clinical signs of chronic polyneuropathy in diabetes. In contrast, motor weakness with loss of the ability to stand on the heels occurs late in the clinical course and only in a minority of diabetic patients. Previous studies on motor function in diabetic neuropathy have relied on simple clinical tests such as the ability to stand on heels (1) and neurophysiological examinations of motor nerves (2). In a series of experiments in long-term diabetic patients, we have observed that muscle weakness in the lower-leg muscles occurs to a substantial degree in chronic neuropathic patients, closely

related to muscle atrophy, whereas non-neuropathic patients have normal muscle strength and striated muscle mass (3). In the more distally situated intrinsic foot muscles, Brash et al. (4) observed atrophy in neuropathic diabetic patients using a specific magnetic resonance imaging (MRI) contrast sequence; however, the atrophy was not quantified. Since diabetic polyneuropathy shows a centripetal pattern of progression, quantification of the more distally situated foot muscles could possibly serve as an early marker for motor dysfunction in diabetic neuropathy.

We hypothesized that muscular atrophy is an integral part of diabetic neurop-

athy that is easily detected in the feet and is closely related to the severity of neuropathy. In the present study, foot muscle volume was studied in a group of long-term diabetic patients with and without neuropathy and in a group of nondiabetic control subjects.

RESEARCH DESIGN AND METHODS

Twenty-three type 1 diabetic patients (16 men and 7 women) aged 46 years (median, range 27–62) with a median diabetes duration of 29 years (range 16–38) were included. The mean body weight and body height were 73 kg (range 53–92) and 176 cm (range 155–186), respectively. Diabetic patients without and with various degrees of neuropathy were selected without paying attention to symptoms and signs of motor disturbances. Patients with severe cardiac or lung disease, acute or chronic musculoskeletal disorders, acute metabolic dysregulation, other neurological or endocrine disorders, or any previous or present lower-limb asymmetric proximal weakness were excluded. None of the patients had a history of foot ulcer or symptoms or signs of arterial insufficiency in the lower extremities. All case records were searched for other explanations of polyneuropathy, and all patients were examined by a trained neurologist who decided whether the findings were typical of diabetic neuropathy. None of the patients had any significant toe or foot deformity. Twenty-three healthy control subjects were included and matched for sex. They had a median age of 46 years (range 27–61), body height of 179 cm (range 160–185), and body weight of 69 kg (range 55–97). All patients and control subjects gave informed consent to the study, which was approved by the local ethics committee.

The nondominant foot of all patients and control subjects was visualized by MRI using a 1.0 Tesla scanner (Sigma GE). All MRI scans were obtained with a conventional T1-weighted Spin-Echo sequence (echo time 20 ms, repetition time 540 ms) using 4-mm cross-sectional magnetic resonance images and an intersec-

From the ¹Department of Neurology, Aarhus University Hospital, Aarhus, Denmark; and the ²Medical Department M (Endocrinology and Diabetes), Aarhus University Hospital, Aarhus, Denmark.

Address correspondence and reprint requests to Henning Andersen, Department of Neurology, Aarhus University Hospital, 8000 Aarhus C, Denmark. E-mail: hande@akhs.phd.dk.

Received for publication 14 April 2004 and accepted in revised form 15 July 2004.

Abbreviations: MRI, magnetic resonance imaging; VFM, volume of the intrinsic foot muscles.

A table elsewhere in this issue shows conventional and Système International (SI) units and conversion factors for many substances.

© 2004 by the American Diabetes Association.

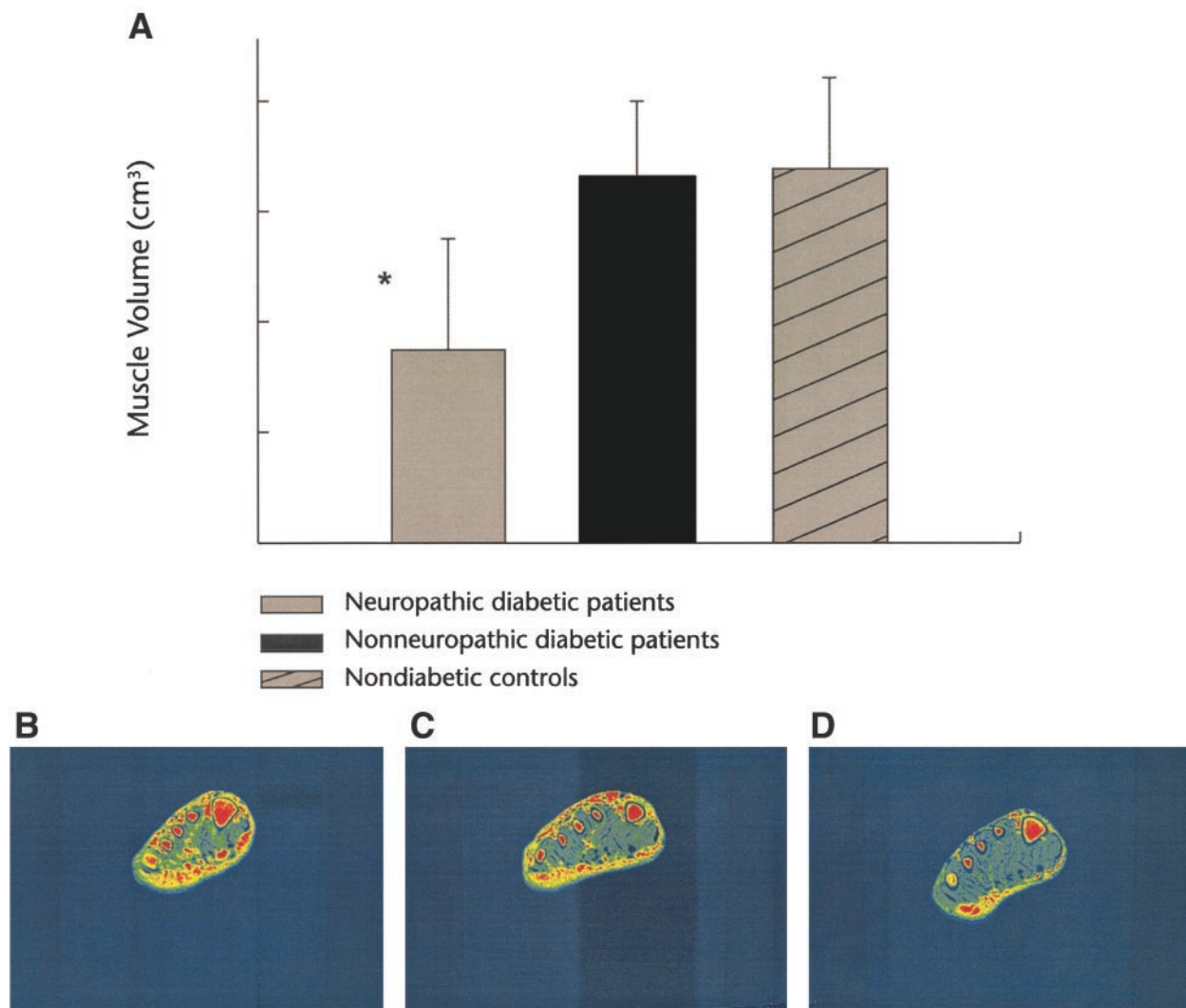


Figure 1—Total volume of all foot muscles in 15 type 1 diabetic patients with neuropathy, in 8 nonneuropathic type 1 diabetic patients, and in 23 nondiabetic healthy control subjects (A). Values are means \pm SD. Below is a cross-sectional magnetic resonance image at the metatarsal level of the foot in a neuropathic patient (B), in a nonneuropathic patient (C), and in a nondiabetic control subject (D) showing that the neuropathic diabetic patient has a substantial reduction of muscle tissues. * $P < 0.001$, neuropathic patients compared with nonneuropathic patients and nondiabetic control subjects.

tion interval of 10 mm. A 256×256 matrix and two excitations were used. The magnetic resonance images were converted to digital pictures for analysis on a PC (Chameleon; Olympus). The identity of the magnetic resonance images was blinded to the observers. Within the muscle compartments, an upper level of signal intensity for muscle tissues was defined. Signal intensities above this level were comparable with signal intensities of fat tissues, allowing a separation of muscle tissues from “nonmuscle tissues” within the muscle compartments. Muscle fascia, tendons, and blood vessels were excluded. At each image, the cross-sectional area of all muscles was estimated

by a single observer using a stereological point-counting method as described previously (3,5). The total volume of striated muscle (in cubic centimeters) was calculated by multiplying the distance between the sections by the total cross-sectional area, the first section being randomly placed within the first interslice 10-mm interval. For further analysis, the volume for each patient was expressed as a percentage of the value of the individually matched control subject.

All patients were evaluated clinically according to a neuropathy symptom score (6) and a neurological impairment score (7). Motor nerve conduction velocity and response amplitudes were deter-

mined for the dominant median and nondominant peroneal nerve using an electromyograph (Dantec Counterpoint) and standard methods. Vibratory perception thresholds were evaluated at the dominant index finger pulp and at the nondominant dorsum of the great toe using forced-choice techniques (Case IV; WR Medical Electronics). A neuropathy rank-sum score was calculated for each patient based on the findings of the neuropathy symptom score, neurological impairment score, vibratory perception threshold test, and motor nerve conduction velocity, a high score reflecting severe nerve dysfunction. The minimal criteria for diabetic neuropathy were adopted and

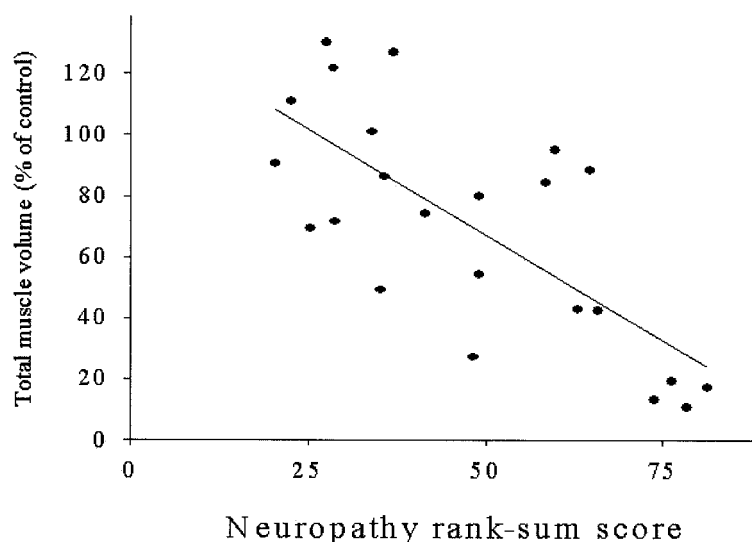


Figure 2—The relationship between the neuropathy rank-sum score and the volume of foot muscles in all diabetic patients given as a percentage of their individually matched control values ($r = -0.75$, $P < 0.0001$).

applied for separation of neuropathic and nonneuropathic patients (1).

Statistical comparisons between groups were made with ANOVA, and correlations were sought for using linear regression analysis.

RESULTS— The diabetic patients had a median neurological impairment score of 7 (range 0–36). According to the minimal criteria for diabetic neuropathy, 15 and 8 patients were defined as neuropathic and nonneuropathic, respectively. Patients with and without neuropathy had a diabetes duration of 30 (range 21–38) and 27 years (range 16–35), respectively ($P = \text{NS}$). Thirteen patients had symptoms of peripheral neuropathy. All had sensory complaints, with paresthesia and/or loss of sensation in the lower extremities. In addition, two patients had neurogenic pain, and six men complained of erectile dysfunction. Only three patients had motor symptoms, all of which involved the ankles. Motor nerve conduction velocity of the median and peroneal nerves was 48.2 m/s (range 41.3–61.0) and 37.1 m/s (range 20.8–45.6), respectively. In three patients, no response could be obtained from the extensor digitorum brevis muscle.

In Fig. 1, volume of the intrinsic foot muscles (VFM), together with an illustrative example of a cross-section of the foot, is shown for each of the three groups. It appears that the VFM of diabetic patients

with neuropathy is one-half that of control subjects and also one-half that of diabetic patients without neuropathy. Expressed relative to their individually matched control subjects, the median VFMs were 49% (range 11–95) and 106% (range 70–130), respectively ($P < 0.01$). In the combined group of diabetic patients with and without neuropathy, there was a close relationship between the neuropathy rank-sum score and the VFM (Fig. 2). Furthermore, the VFM was closely related to the amplitude of the compound muscle action potential of the peroneal nerve ($r = 0.71$, $P < 0.001$), whereas no statistically significant relation was found between the VFM and the motor nerve conduction velocity of the peroneal nerve ($r = 0.42$, $P = 0.06$). No relationship was found between the VFM and duration of diabetes ($r = 0.19$, $P = 0.39$).

CONCLUSIONS— Applying MRI and a stereological point-counting method, we found that total VFM is halved in diabetic patients with chronic neuropathy as compared with that of nonneuropathic diabetic patients and nondiabetic control subjects. In the most advanced cases of neuropathy, volume was $<20\%$ of that of individual control values. Our hypothesis that atrophy of intrinsic foot muscles is a measure closely reflecting motor dysfunction in diabetic neuropathy is supported by the close re-

lationship between degree of atrophy and degree of neuropathy based on clinical, electrophysiological, and quantitative sensory examinations.

Loss of sensation, toe abnormalities, and foot ulcers are easily recognized at the clinical examination of a diabetic foot. In contrast, evaluation of the motor system is hampered by the inability to evaluate the strength of foot muscles and difficulties estimating muscle mass. In a previous study of diabetic patients, we have found a very close relationship between the volume of muscles and strength of ankle dorsal and plantar flexors (r values >0.8) (3). This clearly indicates that determination of muscle mass reflects motor function. In healthy subjects, r values between muscle strength and total muscle volume exceeded 0.85, a slightly closer relation than the one between muscle cross-sectional area and muscle strength (4).

Volume of striated muscles in the foot was determined using a stereological point-counting method (8). This method provides an unbiased estimation of the volume of any structure of interest within an object pending unequivocal definition of the structure, irrespective of the form of the object. In this study, none of the patients had any significant foot or toe deformity. Therefore, a similar orientation of the cross-sectional scans is obtained in the two groups, thereby providing representative views of the striated muscles in both patients and control subjects.

Recently, using MRI in a group of neuropathic patients, Bus et al. (9) observed considerable loss of small foot muscles compared with nondiabetic control subjects. Their study did not include a group of nonneuropathic diabetic patients. We found completely preserved muscle volume in long-term diabetic patients without neuropathy. Despite differences in patient selection and techniques for quantification of muscle mass, the finding of Bus et al. is in accordance with the present observation, emphasizing that diabetic patients with chronic neuropathy have considerable loss of striated muscle in the feet. Atrophy of foot muscles is believed to result in altered architecture of the foot and can thereby cause toe abnormalities (clawing, hammering) (10). Together with sensory loss, this will lead to callus formation and ultimately to foot ulcers. Interestingly, in the study by Bus et al. some patients had atrophy without toe deformities, whereas the opposite was

not the case. In our study, no patient had any significant foot or toe deformity. This supports the notion that loss of foot muscles precedes development of toe abnormalities.

Ultrasonography has been applied more frequently than MRI in studies of the diabetic foot. An inverse relationship has been found between the plantar fascia thickness and the dynamic foot pressure (11), and changes in the structure of the plantar fascia seem to influence the joint mobility of the first metatarsophalangeal joint (12). No ultrasonographic study has been performed to quantify the amount of striated muscles in the diabetic foot.

In patients with peripheral arterial occlusive disease, strength of the dorsiflexors is reduced compared with age-matched control subjects (13) and atrophy of muscle fibers can occur. Diabetic patients often have macrovascular complications that could contribute to such atrophy. However, in this study none of the patients had intermittent claudication, all walked independently, and none had a history of foot ulcers. Furthermore, the median age of the patients was only 47 years, which makes arterial insufficiency and physical inactivity an unlikely explanation for the profound atrophy observed.

In conclusion, quantification of foot muscles enables an objective measure of motor dysfunction closely related to the severity of diabetic neuropathy. Monitoring of VFM may be helpful in treatment trials. However, larger-scaled prospective studies are needed to elucidate the rele-

vance of quantitating foot muscle atrophy in relation to other neuropathic manifestations. Because MRI is a relatively time-consuming and expensive technique, an easier-to-perform evaluation of muscle volume is needed.

Acknowledgments— This study was supported in part by the Karen Elise Jensen Foundation, the Research Initiative of Aarhus University Hospital, and the Danish Diabetes Association.

References

1. Dyck PJ, Kratz KM, Karnes JL, Litchy WJ, Klein R, Pach JM, Wilson DM, O'Brien PC, Melton LJ 3rd, Service FJ: The prevalence by staged severity of various types of diabetic neuropathy, retinopathy, and nephropathy in a population-based cohort: the Rochester Diabetic Neuropathy Study. *Neurology* 43:817–824, 1993
2. Thomas PK, Tomlinson DR: Diabetic and hypoglycemic neuropathy. In *Peripheral Neuropathy*. 3rd ed. Dyck PJ, Thomas PK, Griffin JW, Low PA, Poduslo JF, Eds. Saunders, Philadelphia, 1993, p. 1219–1250
3. Andersen H, Gadeberg PC, Brock B, Jakobsen J: Muscular atrophy in diabetic neuropathy: a stereological magnetic resonance imaging study. *Diabetologia* 40:1062–1069, 1997
4. Brash PD, Foster J, Vennart W, Anthony P, Tooke JE: Magnetic resonance imaging techniques demonstrate soft tissue damage in the diabetic foot. *Diabet Med* 16:55–61, 1999
5. Gadeberg P, Andersen H, Jakobsen J: Volume of ankle dorsiflexors and plantar flexors determined with stereological techniques. *J Appl Physiol* 86:1670–1675, 1999
6. Dyck PJ, Sherman WR, Hallcher LM, Service FJ, O'Brien PC, Grina LA, Palumbo PJ, Swanson CJ: Human diabetic endoneurial sorbitol, fructose, and myo-inositol related to sural nerve morphometry. *Ann Neurol* 8:590–596, 1980
7. Dyck PJ: Quantitating severity of neuropathy. In *Peripheral Neuropathy*. 3rd ed. Dyck PJ, Thomas PK, Griffin JW, Low PA, Poduslo JF, Eds. Saunders, Philadelphia, 1993, p. 686–697
8. Gundersen HJ, Jensen EB: The efficiency of systematic sampling in stereology and its prediction. *J Microsc* 147:229–263, 1987
9. Bus SA, Yang QX, Wang JH, Smith MB, Wunderlich R, Cavanagh PR: Intrinsic muscle atrophy and toe deformity in the diabetic neuropathic foot: a magnetic resonance imaging study. *Diabetes Care* 25:1444–1450, 2002
10. Boulton AJ: The pathogenesis of diabetic foot problems: an overview. *Diabet Med* 13 (Suppl. 1):S12–S16, 1996
11. Abouaisha F, van Schie CH, Griffiths GD, Young RJ, Boulton AJ: Plantar tissue thickness is related to peak plantar pressure in the high-risk diabetic foot. *Diabetes Care* 24:1270–1274, 2001
12. D'Ambrogi E, Giurato L, D'Agostino MA, Giacomozzi C, Macellari V, Caselli A, Uccioli L: Contribution of plantar fascia to the increased forefoot pressures in diabetic patients. *Diabetes Care* 26:1525–1529, 2003
13. Scott-Okafor HR, Silver KK, Parker J, Almy-Albert T, Gardner AW: Lower extremity strength deficits in peripheral arterial occlusive disease patients with intermittent claudication. *Angiology* 52:7–14, 2001