

# Plantar Fat-Pad Displacement in Neuropathic Diabetic Patients With Toe Deformity

## A magnetic resonance imaging study

SICCO A. BUS, MSc<sup>1</sup>  
MARIO MAAS, MD, PhD<sup>2</sup>  
PETER R. CAVANAGH, PhD, DSc<sup>3</sup>

ROBERT P. J. MICHELS, MD, PhD<sup>1</sup>  
MARCEL LEVI, MD, PhD<sup>1</sup>

**OBJECTIVE** — The aim of this study was to quantify the association between claw/hammer toe deformity and changes in submetatarsal head (sub-MTH) fat-pad geometry in diabetic neuropathic feet.

**RESEARCH DESIGN AND METHODS** — Thirteen neuropathic diabetic subjects (mean age 56.2 years) with toe deformity, 13 age- and sex-matched neuropathic diabetic control subjects without deformity, and 13 age- and sex-matched healthy control subjects without deformity were examined. From high-resolution sagittal plane magnetic resonance images of the second and third ray of the foot, toe angle (a measure of deformity), sub-MTH fat-pad thickness, and subphalangeal fat-pad thickness were measured. The ratio of these thicknesses was used to indicate fat-pad displacement.

**RESULTS** — Sub-MTH fat pads were significantly thinner ( $2.5 \pm 1.3$  vs.  $6.0 \pm 1.4$  mm,  $P < 0.001$ ) and subphalangeal fat pads significantly thicker ( $9.1 \pm 1.9$  vs.  $7.6 \pm 1.2$  mm,  $P < 0.005$ ) in the neuropathic group with deformity compared with neuropathic control subjects. As a result, thickness ratio was substantially smaller in the deformity group:  $0.28 \pm 0.14$  vs.  $0.79 \pm 0.14$  in neuropathic control subjects ( $P < 0.001$ ). A significant correlation of 0.85 was present between toe angle and thickness ratio ( $P < 0.001$ ). No significant differences were found between neuropathic and healthy control subjects.

**CONCLUSIONS** — This study shows a distal displacement and subsequent thinning of the sub-MTH fat pads in neuropathic diabetic patients with toe deformity and suggests that, as a result, the capacity of the tissue in this region to reduce focal plantar pressure is severely compromised. This condition is likely to increase the risk of plantar ulceration in these patients.

*Diabetes Care* 27:2376–2381, 2004

At pads under the metatarsal heads (MTHs) in the foot provide the primary source of cushioning to protect the skin from damage during gait. These

fat pads are invested in the flexor tendons of the toes and originate from the plantar ligaments, which are firmly attached to the proximal phalanges (1,2). In clawing

and hammering of the toes, the sub-MTH fat pads are believed to migrate distally as a result of hyperextension of the metatarsal-phalangeal (MTP) joint, exposing the now prominent and unprotected MTHs to elevated levels of mechanical pressure during gait (1,3–5). Elevated plantar pressure has long been established as a major risk factor for plantar ulceration in diabetic neuropathic feet (6,7).

Dissection of nondiabetic cadaver feet with hammered toes has shown a distal pull of the plantar fat pad with substantial thinning or even loss of sub-MTH fat tissue and thickening of fat tissue plantar to the proximal phalanx (1). However, despite numerous theoretical and anecdotal reports, there is no quantitative in vivo evidence of fat-pad displacement and resultant thinning of sub-MTH fat tissue secondary to toe deformity in neuropathic diabetic patients.

Clawing/hammering of the toes, which is a common deformity in diabetic patients (8,9), has been shown to be a significant predictor of elevated plantar pressure in neuropathic diabetic patients (10) and, prospectively, of foot ulceration in people with diabetes (11). Therefore, the study of above-mentioned mechanism is important to improve our understanding of the role toe deformity plays in causing plantar ulceration. Because magnetic resonance imaging (MRI) has emerged as the most useful noninvasive tool with which fatty structures can be studied (12), we used this technique to determine, in diabetic neuropathic feet, the association between MTP joint hyperextension and changes in plantar fat-pad geometry.

## RESEARCH DESIGN AND METHODS

Thirteen diabetic patients with distal symmetric sensory neuropathy and MTP joint hyperextension deformity (experimental group) and 13 age- and sex-matched diabetic patients with neuropathy but without toe defor-

From the <sup>1</sup>Department of Internal Medicine, Academic Medical Center, University of Amsterdam, Amsterdam, the Netherlands; the <sup>2</sup>Department of Radiology, Academic Medical Center, University of Amsterdam, Amsterdam, the Netherlands; and the <sup>3</sup>Department of Biomedical Engineering, Lerner Research Institute, The Cleveland Clinic Foundation, Cleveland, Ohio.

Address correspondence and reprint requests to Sicco A. Bus, MSc, Department of Internal Medicine, Room F4-252, Academic Medical Center, University of Amsterdam, P.O. Box 22700, 1100 DE Amsterdam, Netherlands. E-mail: s.a.bus@amc.uva.nl.

Received for publication 23 March 2004 and accepted in revised form 25 June 2004.

**Abbreviations:** MRI, magnetic resonance imaging; MTH, metatarsal head; MTP, metatarsal-phalangeal; VPT, vibration perception threshold.

A table elsewhere in this issue shows conventional and Système International (SI) units and conversion factors for many substances.

© 2004 by the American Diabetes Association.

Table 1—Baseline subject characteristics and experimental results for the three study groups

	Neuropathic experimental	Neuropathic control	Healthy control
n	13	13	13
Age (years)	56.3 ± 8.6	57.2 ± 6.5	53.9 ± 6.8
Height (m)	1.77 ± 0.10	1.74 ± 0.06	1.73 ± 0.08
Weight (kg)	85.5 ± 14.6	79.5 ± 10.3	79.3 ± 10.6
BMI (kg/m <sup>2</sup> )	27.2 ± 2.9	26.4 ± 4.1	26.6 ± 4.2
Diabetes type (1/2)	9/4	11/2	—
Diabetes duration (years)	32.8 ± 12.0	31.1 ± 12.8	—
HbA <sub>1c</sub> (%)	7.8 ± 1.1	8.0 ± 0.9	—
History of ulceration (plantar MTHs excluded)	3	2	—
Neuropathy duration (years)*	12.4 ± 5.3	11.6 ± 7.6	—
Vibration perception threshold (volts)	33.5 ± 12.2	36.2 ± 10.6	11.6 ± 4.3
Foot studied (L/R)	6/7	6/7	5/8
Number of toes	21	21	19
Toe angle (α, degrees)	−25.2 ± 10.0	−2.0 ± 5.7†	−3.9 ± 5.9†
Fat-pad thickness (mm)			
Sub-MTH	2.5 ± 1.3	6.0 ± 1.4†	6.0 ± 1.2†
Subphalangeal	9.1 ± 1.9	7.6 ± 1.2‡	7.7 ± 1.3§
Thickness ratio	0.28 ± 0.14	0.79 ± 0.14†	0.78 ± 0.10†

Data are means ± SD. VPTs for healthy subjects were all within normal limits (14). \*As derived from medical records or, when absent, estimated by the patient based on the first appearance of neuropathic symptoms. †P < 0.001, ‡P < 0.005, and §P < 0.05 compared with neuropathic experimental group. ||P < 0.001 compared with both neuropathic subject groups.

mity (neuropathic control group) participated. An age- and sex-matched group of 13 healthy subjects without toe deformity (healthy control group) was also included. Subjects in the experimental group were selected based on deformity present in at least the second or third ray of the foot that was assessed clinically and later confirmed by MRI evaluation as described below. Each group consisted of eight men and five women. The maximum age difference between matched subjects was 6 years. Subject characteristics are summarized in Table 1.

Subjects were classified as neuropathic if they exhibited loss of protective sensation, based on the inability to feel the touch of a 10-g monofilament at one or more of six sites on the plantar surface of the foot (13). Vibration perception threshold (VPT) was also measured according to standardized methods (7) on the dorsal surface of the hallux using a Biothesiometer (Bio-Medical Instrument Company, Newbury, OH). All subjects had abnormal VPT based on the 95% age-appropriate confidence intervals for VPT (14).

Exclusion criteria were: 1) age <40 or >65 years; 2) significant peripheral vascular disease, determined by absent dorsalis pedis or tibialis posterior arterial pulses, combined with an ankle-brachial systolic blood pressure index <0.75 or a

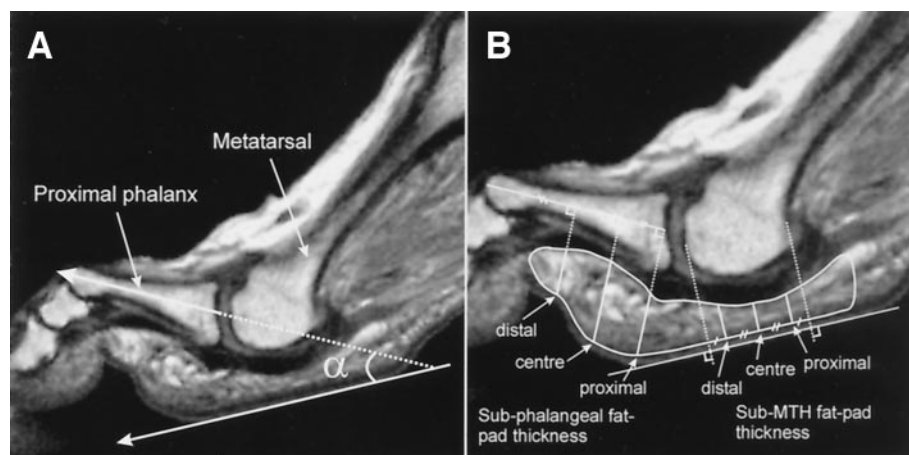
toe pressure <50 mmHg; 3) neuropathic syndromes other than distal symmetrical neuropathy associated with diabetes; 4) significant musculoskeletal disorders in the lower extremities, including injury, fracture, and surgery; 5) rheumatoid arthritis, lower-extremity amputation, or Charcot neuroarthropathy; 6) history of ulceration in the plantar MTH region; 7) current foot ulceration or edema; and 8) conditions precluding MRI. This study was approved by the medical ethics committee of the Academic Medical Center of the University of Amsterdam. Written informed consent was obtained from each subject.

A Siemens 1.5-Tesla Magnetom 63SP/4000 imager (Siemens, Erlangen, Germany) was used to acquire high-resolution (512 × 512 pixels) T<sub>1</sub>-weighted sagittal plane spin-echo images of the foot. Subjects lay supine with one foot inserted into a circular polarized head coil, which provided the best signal-to-noise ratio for studying the foot (12). Without affecting the natural non-weight-bearing configuration of the toes, the foot was immobilized on a 60-degree wooden ramp using tape and padding to minimize motion artifacts during image acquisition. The foot used for MRI data collection was randomly assigned if either foot was not excluded by the aforementioned criteria.

The dataset consisted of 19 slices collected between the first and fifth MTHs. Their anatomical orientation was parallel to the long axis of the second metatarsal in a transverse plane and perpendicular to the sole of the forefoot in a coronal plane. Repetition time was 577 ms, echo time 17 ms, slice thickness 3 mm, interslice gap 0.9 mm, and field of view 256 × 256 mm. Acquisition time was 10 min per subject. Representative slices through the second and third MTP joints were selected for quantitative analysis. In some cases, measurements were made from an additional adjacent slice as a result of anatomical misalignment in the sampling plane.

Using Agfa IMPAX WEB1000 software (Agfa-Gevaert N.V., Mortsel, Belgium), the degree of hyperextension deformity was assessed from the MR images by measuring the angle α (called the “toe angle”—negative value denoting extension) between a line parallel to the sole of the forefoot and the bisector of the proximal phalanx (Fig. 1A). All neuropathic subjects with deformity had a toe-extension angle that was a minimum of 2 SD larger than the average toe angle in the neuropathic control subjects. Average toe angles are shown in Table 1.

To improve visualization of plantar fat tissue, the image resolution was increased threefold through interpolation using an eFilm workstation (Merge-



**Figure 1**—A: Configuration of the MTP joint defined by the angle between a line parallel to the sole of the forefoot and the bisector of the proximal phalanx. The angle  $\alpha$  was named the toe angle, with a negative sign representing extension. B: Representative sagittal-plane image through the MTP joint of the second ray. Sub-MTH and subphalangeal fat-pad thickness were both measured at three proximal-to-distal locations, the former perpendicular to the sole of the foot and the latter perpendicular to the bisector of the proximal phalanx.

eFilm, Milwaukee, WI), resulting in pixel dimensions of  $0.17 \times 0.17$  mm. The plantar fat pad was defined as the structure with the highest signal intensity between the bone and the skin. It was measured between the lower signal intensity structures dorsally (tendon and connective tissue) and plantarly (subcutis). Fat-pad thickness was measured plantar to the MTH and plantar to the proximal phalanx using Scion Image (National Institutes of Health, Bethesda, MD). Sub-MTH fat-pad thickness was measured perpendicular to the sole of the foot, and subphalangeal fat-pad thickness was measured perpendicular to the bisector of the proximal phalanx. In both regions, measurements at proximal, central, and

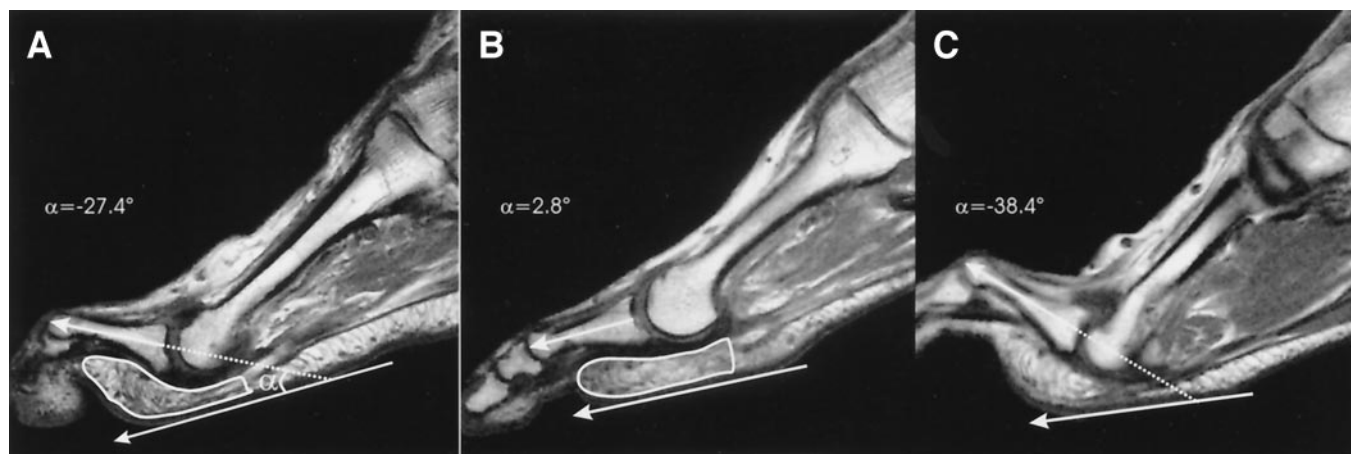
distal locations were made to provide a good representation of fat-pad thickness throughout the region (Fig. 1B). The average thickness of these three measures per region was used for further analysis. The ratio of sub-MTH to subphalangeal fat-pad thickness was also calculated and was used as an indicator of fat-pad displacement.

#### Statistical analysis

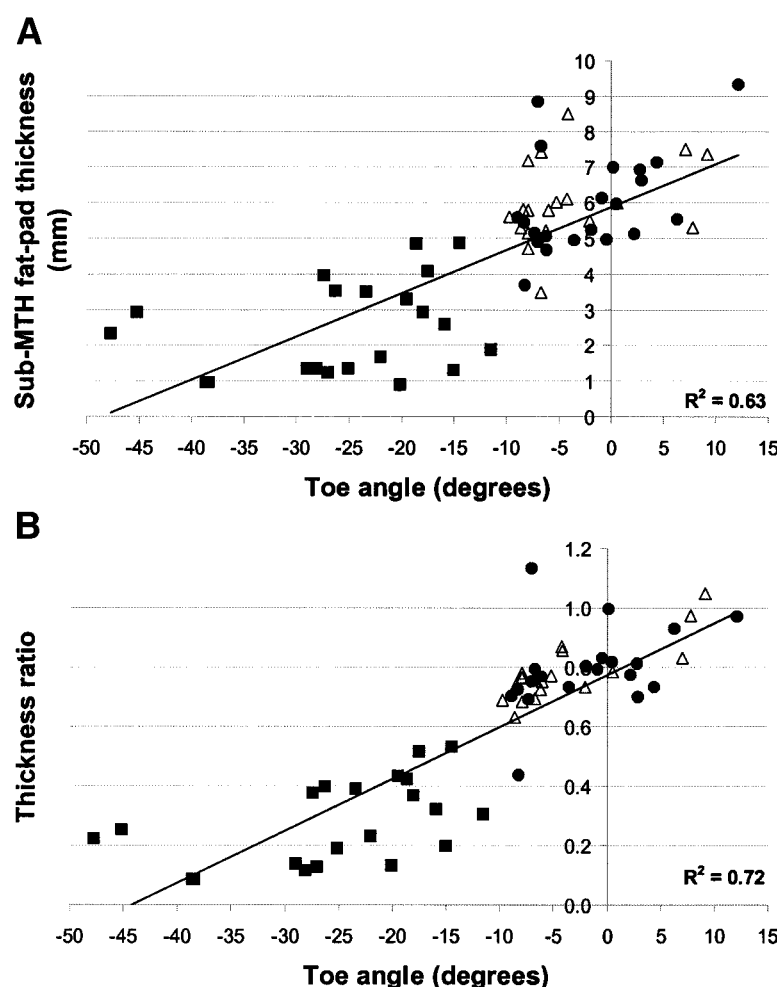
From each subject group, 26 toes (both second and third digits) were available for analysis. Five toes (from different subjects in the experimental group) were excluded because they did not meet the criterion for deformity (four toes) or could not be examined due to inadequate MRI slice ori-

entation (one toe). In the healthy control group, two toes from one subject were excluded because they were abnormally aligned. Thus, 21 toes were evaluated from both neuropathic groups and 19 toes in the healthy control group.

Differences between the subject groups for each dependent variable in the study were examined using one-way analyses of variance with Tukey post hoc pairwise comparison using SPSS statistical software (SPSS, Chicago, IL). Pearson correlation coefficients were calculated between selected variables of interest for the pooled data of 26 neuropathic subjects ( $n = 42$  toes). The data were pooled because the two neuropathic groups showed a continuous spectrum for toe an-



**Figure 2**—Joint configuration and fat-pad geometry in a neuropathic subject with deformity of the second digit (A) and a matched neuropathic subject with a normally aligned second toe (B). Note the remarkable difference in geometry of the plantar fat pads between the subjects. C: Example of a neuropathic subject with toe deformity and almost complete absence of sub-MTH fat tissue.



**Figure 3**—Scatter plots for the association between toe angle and sub-MTH fat-pad thickness (A) and between toe angle and thickness ratio (B) for the three subject groups (■, experimental group; ●, neuropathic control group; △, healthy control group). Linear regression lines and  $R^2$  values are added for the pooled group of neuropathic subjects ( $n = 42$ ).

gle measures. A significance level of  $P < 0.05$  was used for all analyses.

**RESULTS**— Baseline characteristics showed no significant differences between the groups, except for VPT, which was significantly lower in the healthy control group when compared with the two neuropathic groups (Table 1).

An initial qualitative evaluation of the MRIs showed differences in fat-pad geometry between the deformed and normally aligned toes of the neuropathic subjects (Fig. 2) with thinner sub-MTH fat pads and thicker subphalangeal fat pads in the deformed cases. In 10 of the 21 deformed toes, fat tissue was discontinuous and almost completely absent from the sub-MTH region (Fig. 2C).

The sub-MTH fat pads were signifi-

cantly thinner in the experimental group compared with the neuropathic control group ( $P < 0.001$ ), whereas the subphalangeal fat pads were significantly thicker ( $P < 0.005$ ) (Table 1). As a result, the ratio of sub-MTH to subphalangeal fat-pad thickness was substantially smaller (by 65%) in the experimental group ( $P < 0.001$ ). The subphalangeal fat pads were 3.6 times thicker than the sub-MTH fat pads in the experimental group and 1.3 times thicker in the neuropathic control subjects. In all 21 deformed toes examined, sub-MTH fat-pad thickness and thickness ratio were smaller than in their matched controls. Toe angle ( $\alpha$ ) was significantly correlated with sub-MTH fat-pad thickness ( $r = 0.80$ ,  $P < 0.001$ ) (Fig. 3A), subphalangeal fat-pad thickness ( $r = -0.57$ ,  $P < 0.001$ ), and thickness ratio

( $r = 0.85$ ,  $P < 0.001$ ) (Fig. 3B). Thickness ratio and sub-MTH fat-pad thickness were also significantly correlated ( $r = 0.88$ ,  $P < 0.001$ ). The healthy control subjects and the neuropathic control subjects were not significantly different from each other on any of the dependent variables.

**CONCLUSIONS**— The results of this study show that the geometry of the plantar fat pad is remarkably different between neuropathic patients with and without toe deformity, with significantly thinner sub-MTH fat pads and significantly thicker subphalangeal fat pads when deformity is present. Deformity was associated with a 65% reduction in the ratio of sub-MTH to subphalangeal fat-pad thickness, indicating that the sub-MTH fat-pad cushions are distally displaced. In support of this finding, strong and highly significant correlations were found between toe angle and thickness ratio ( $r = 0.85$ ), toe angle and sub-MTH fat-pad thickness ( $r = 0.80$ ), and toe angle and subphalangeal fat-pad thickness ( $r = -0.57$ ), showing that pathological changes were more apparent with more severe cases of deformity. In nearly one-half of the deformed toes, a discontinuity and almost complete absence of fat tissue was found in the sub-MTH region (Fig. 2C). It is possible that the plantar fat pad ruptured in these cases.

The present objective in vivo findings confirm anecdotal reports and observational studies on diabetic neuropathic feet (3) and nondiabetic cadaver specimens (1). Ellenberg (3) postulated that a hyperextended position of the toes at the MTP joint leads to uncovered and readily palpable MTHs, resulting in elevated pressure and trauma to soft tissues during ambulation. Bojsen-Moller (1) stated that, because the sub-MTH fat-pad cushions are indirectly connected to the proximal phalanx via the entrapment in vertical fibers and investment in the flexor tendons, they are displaced distally when the proximal phalanx is hyperextended.

The healthy and neuropathic control groups, who had comparable average toe angles, were not significantly different in fat-pad thickness and thickness ratio (Table 1), which suggests that diabetic neuropathy per se does not induce changes in fat-pad geometry. This finding contradicts that of Gooding et al. (15), who, us-

ing ultrasound, showed MTH plantar soft tissue thickness reductions in diabetic patients (with and without foot ulcers) compared with healthy control subjects. However, neuropathic status and toe deformity were not assessed in their study. Moreover, active ulceration underneath the MTHs represents a pathological state that may lead to different outcomes. In support of the present findings, Robertson et al. (16), using computed tomography, found no difference in sub-MTH soft-tissue thickness between neuropathic diabetic patients and matched healthy control subjects. However, the measured MTP joint angle was extended more in their neuropathic group and was not correlated with soft-tissue thickness, which does not agree with the present findings. In both referenced studies, soft-tissue thickness from the plantar border of the MTH to the skin was measured, whereas in the present study, only fat-tissue thickness was assessed. This may explain the differences between our study and those of other authors.

Our findings imply that, in feet with claw/hammer toe deformity, the sub-MTH region becomes less functional for bearing weight during gait, leading to elevated plantar pressures and a concomitant higher risk for plantar ulceration in patients who have lost protective sensation. In a separate study reported elsewhere (17), we measured barefoot plantar pressure in the same sample of subjects. Peak pressures at the second and third MTH during walking were significantly higher in the neuropathic subjects with toe deformity when compared with the neuropathic control subjects. The load on the toes was significantly smaller in the neuropathic group with deformity. In the group of neuropathic subjects, there were also highly significant correlations among MTH peak pressure, degree of toe deformity, sub-MTH fat pad thickness, and thickness ratio in these central forefoot regions. Taken together, these two studies show the importance of the toes and the sub-MTH structures in the functioning of the foot. In further support of these data, sub-MTH tissue thickness has been found to be significantly inversely related to peak pressures in the second and third MTH regions of the foot in neuropathic diabetic patients (18). Additionally, hammertoe deformity was prospectively found to be a significant risk factor for plantar ulceration (11).

The present study has a number of limitations. First, its cross-sectional design limits the establishment of a cause-and-effect relationship between deformity and plantar fat-pad changes. However, the similarity between the two neuropathic subject groups in diabetes-related baseline characteristics established, in our opinion, a useful model in which this association could be studied. The combined reduction in sub-MTH fat-pad thickness and the increase in subphalangeal fat-pad thickness, together with multiple highly significant correlations among the dependent variables, suggest a causal link between toe deformity, fat-pad displacement, and thinning of sub-MTH fat tissue. The clinical observations from Bojsen-Moller (1) support this conclusion. Second, in measuring fat-pad thickness, no correction was made for the presence of several nonfatty structures (e.g., blood vessels, plantar aponeurosis, and fibroelastic septae) in these fat compartments (2,19) or for the suggested presence of neuropathy-induced fibrotic atrophy of fat tissue (20). It is unlikely that this last factor affected the comparison between the two neuropathic groups, but it may have influenced the comparison between neuropathic and healthy control subjects. Finally, the process of fat-pad thickness measurement was not blinded because the presence of toe deformity was always apparent when the MR images were viewed. This was, however, unavoidable because the borders of the MTH and proximal phalanx were used to define the region of interest in which fat-pad thickness was measured (Fig. 1B).

Despite the high prevalence of claw/hammer toe deformity in diabetic subjects (values of 32 and 46% have been reported) (8,9) and other groups (21), studies on the mechanical implications of this condition are rare. Ours is the first study to quantify plantar fat-pad changes with toe deformity, whereas previously we have shown with MRI that intrinsic muscle atrophy does not necessarily predispose a foot to exhibit claw/hammer toe deformity (22). Our data justify the exploration of mechanisms leading to this condition so that our understanding of diabetic foot ulcer etiology can be further improved. Although MRI is not cost-effective for assessing the risk of ulceration in diabetic feet with toe deformity, the strong associations found in the present study suggest that measures of toe

angle, perhaps combined with palpation of the MTH, can be used as a good indicator of reduced fat-pad thickness and possible ulcer risk.

In conclusion, the results of this study confirm the long-held belief that claw/hammer toe deformity leads to sub-MTH fat-pad displacement in the neuropathic diabetic foot. The biomechanics of gait will be altered in these patients, leading to a higher risk for the development of plantar foot ulcers.

**Acknowledgments**—The authors would like to thank Ruud Smit, Radiological Technician, and Dr. Erik M. Akkerman, Clinical Physicist, for their assistance in MRI data collection and analysis.

## References

- Bojsen-Moller F: Anatomy of the forefoot, normal and pathologic. *Clin Orthop Rel Res* 142:10–18, 1979
- Bojsen-Moller F, Flagstad KE: Plantar aponeurosis and internal architecture of the ball of the foot. *J Anat* 121:599–611, 1976
- Ellenberg M: Diabetic neuropathic ulcer. *J Mt Sinai Hosp N Y* 35:585–594, 1968
- Sumpio BE: Foot ulcers. *N Engl J Med* 343:787–793, 2000
- Shaw JE, Boulton AJ: The pathogenesis of diabetic foot problems: an overview. *Diabetes* 46 (Suppl. 2):S58–S61, 1997
- Veves A, Murray HJ, Young MJ, Boulton AJ: The risk of foot ulceration in diabetic patients with high foot pressure: a prospective study. *Diabetologia* 35:660–663, 1992
- Pham H, Armstrong DA, Harvey C, Harkless LB, Giurini JM, Veves A: Screening techniques to identify people at high risk for diabetic foot ulceration. *Diabetes Care* 23:606–611, 2000
- Smith DG, Barnes BC, Sands AK, Boyko EJ, Ahroni JH: Prevalence of radiographic foot abnormalities in patients with diabetes. *Foot Ankle Int* 18:342–346, 1997
- Holewski JJ, Moss KM, Stess RM, Graf PM, Grunfeld C: Prevalence of foot pathology and lower extremity complications in a diabetic outpatient clinic. *J Rehabil Res Dev* 26:35–44, 1989
- Mueller MJ, Hastings M, Commean PK, Smith KE, Pilgram TK, Robertson D, Johnson J: Forefoot structural predictors of plantar pressures during walking in people with diabetes and peripheral neuropathy. *J Biomech* 36:1009–1017, 2003
- Boyko EJ, Ahroni JH, Stensel V, Forsberg RC, Davignon DR, Smith DG: A prospective study of risk factors for diabetic foot ulcer: the Seattle Diabetic Foot Study. *Diabetes Care* 22:1036–1042, 1999

12. Maas M, Dijkstra PF, Akkerman EM: Uniform fat suppression in hands and feet through the use of two-point Dixon chemical shift MR imaging. *Radiology* 210:189–193, 1999
13. McNeely MJ, Boyko EJ, Ahroni JH, Stensel VL, Reiber GE, Smith DG, Pecoraro RF: The independent contributions of diabetic neuropathy and vasculopathy in foot ulceration: how great are the risks? *Diabetes Care* 18:216–219, 1995
14. Bloom S, Till S, Sonksen P, Smith S: Use of a biothesiometer to measure individual vibration thresholds and their variation in 519 non-diabetic subjects. *Br Med J (Clin Res Ed)* 288:1793–1795, 1984
15. Gooding GA, Stess RM, Graf PM, Moss KM, Louie KS, Grunfeld C: Sonography of the sole of the foot: evidence for loss of foot pad thickness in diabetes and its relationship to ulceration of the foot. *Invest Radiol* 21:45–48, 1986
16. Robertson DD, Mueller MJ, Smith KE, Commean PK, Pilgram T, Johnson JE: Structural changes in the forefoot of individuals with diabetes and a prior plantar ulcer. *J Bone Joint Surg Am* 84A:1395–1404, 2002
17. Bus SA, Maas M, de Lange A, Michels RPJ, Levi M: Elevated plantar pressure in neuropathic diabetic patients with claw/hammer toe deformity. *J Biomech*. In press
18. Abouaesha F, van Schie CH, Griffiths GD, Young RJ, Boulton AJ: Plantar tissue thickness is related to peak plantar pressure in the high-risk diabetic foot. *Diabetes Care* 24:1270–1274, 2001
19. Jahss MH, Michelson JD, Desai P, Kaye R, Kummer F, Buschman W, Watkins F, Reich S: Investigations into the fat pads of the sole of the foot: anatomy and histology. *Foot Ankle* 13:233–242, 1992
20. Brash PD, Fostert J, Vennart W, Anthony P, Tooke JE: Magnetic resonance imaging techniques demonstrate soft tissue damage in the diabetic foot. *Diabet Med* 16:55–61, 1999
21. Masson EA, Hay EM, Stockley I, Veves A, Betts RP, Boulton AJM: Abnormal foot pressures alone may not cause ulceration. *Diabet Med* 6:426–428, 1989
22. Bus SA, Yang QX, Wang JH, Smith MB, Wunderlich R, Cavanagh PR: Intrinsic muscle atrophy and toe deformity in the diabetic neuropathic foot: a magnetic resonance imaging study. *Diabetes Care* 25:1444–1450, 2002